

Narrow Ridge

Best combination for
narrow ridge



Narrow Ridge

004 I. SmarThor™

007 II. BonEx Kit™

011 III. Clinical Cases

Narrow Ridge

I. SmarThor™

: Most simple and easy to split

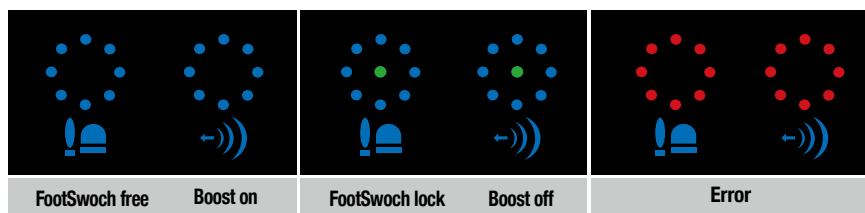
Description	Color	Ref.C
SmarThor (2 SmarThor tips included, 1 Sliver Tip, 1 Gold Tip)	White	DMT-THOR-W
	Red	DMT-THOR-R
SmarThor Tip	Sliver	DMT-THOR-TS

1. Simple and strong at the reasonable price



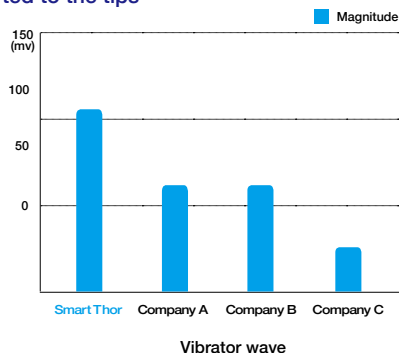
- Simple

Only Three buttons! : On & Off, Foot switch, Power Boost



- Strong

Comparison of vibration wave transmitted to the tips



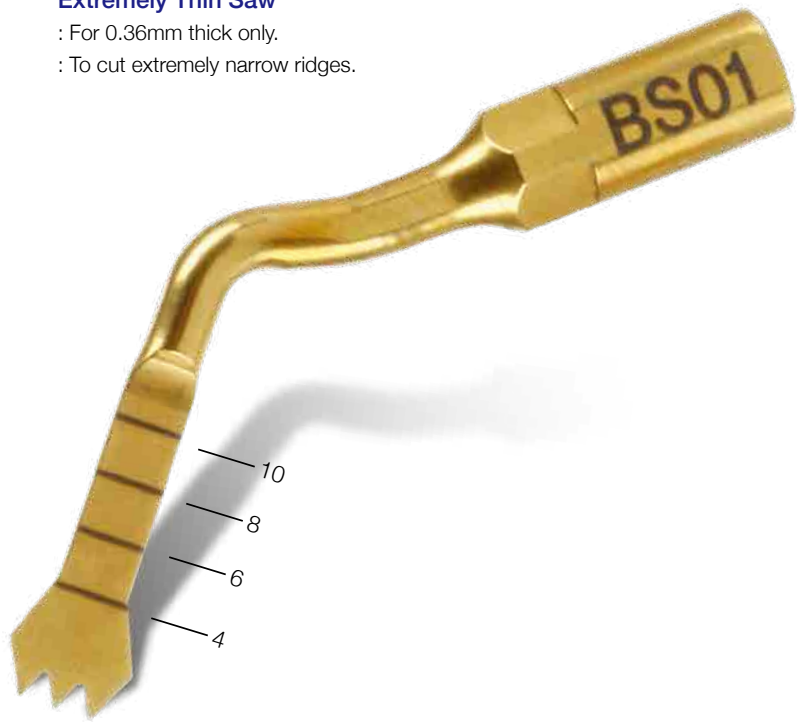Measurement of vibration frequency at the end of saw

Devices used	Measurements of Tip End Vibration Frequency
SmarThor	28.18 kHz
Company D	28.09 kHz
Company M	27.14 kHz
Company E	27.94 kHz
Company S	28.33 kHz
Company A	29.88 kHz

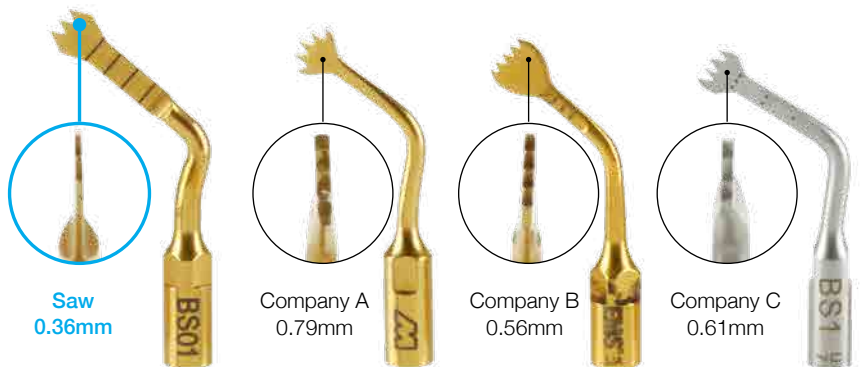
2. Specially Designed Saw for Ridge Splitting

Calibrations to see the depth of cut!
: 4, 6, 8 and 10mm

Extremely Thin Saw
: For 0.36mm thick only.
: To cut extremely narrow ridges.



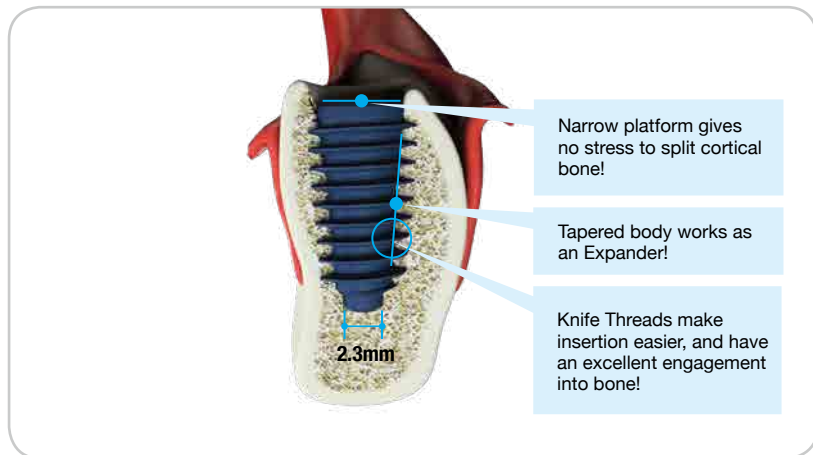
Saw compatability with other piezo machines



Company	Product
Company M	PIEZO SURGERY
Company S	Surgybone
Company E	Surgysonic
Company D	Sonic Surgeon 300

3. Perfect match with the AnyRidge® Implants

Well tapered body, Knife Threads and Narrow Platform makes Ridge Splitting more effective!



• Knife(Deep) Thread

The powerful self-tapping thread provides an incredible initial stability with increased resistance to compressive force while minimizing the generation of shear force.

• Tapered body

As the core is narrow & uniformed, the implant can be placed as a horizontal bone incision during ridge splitting resulting in better initial stability and less stress to the bone.

• Less reduction and Better Preservation of cortical bone

AnyRidge's macro shape helps maintain more buccal and lingual cortical bone than any other implant system in the market today. The unique shape of the implant with a narrow core and varying thread depths enables wider diameter implants to be placed into narrow ridges.

AnyRidge, the Thinking Man's Privilege

- Always guarantees excellent initial stability
- Less reduction and better preservation of cortical bone
- Wider implant is possible than the cortical width
- Strong body and greater surface area

4. Economical


**Only 'One' Ridge Splitting Case
can cover the cost of a SmarThor!**

II. BonEx Kit™

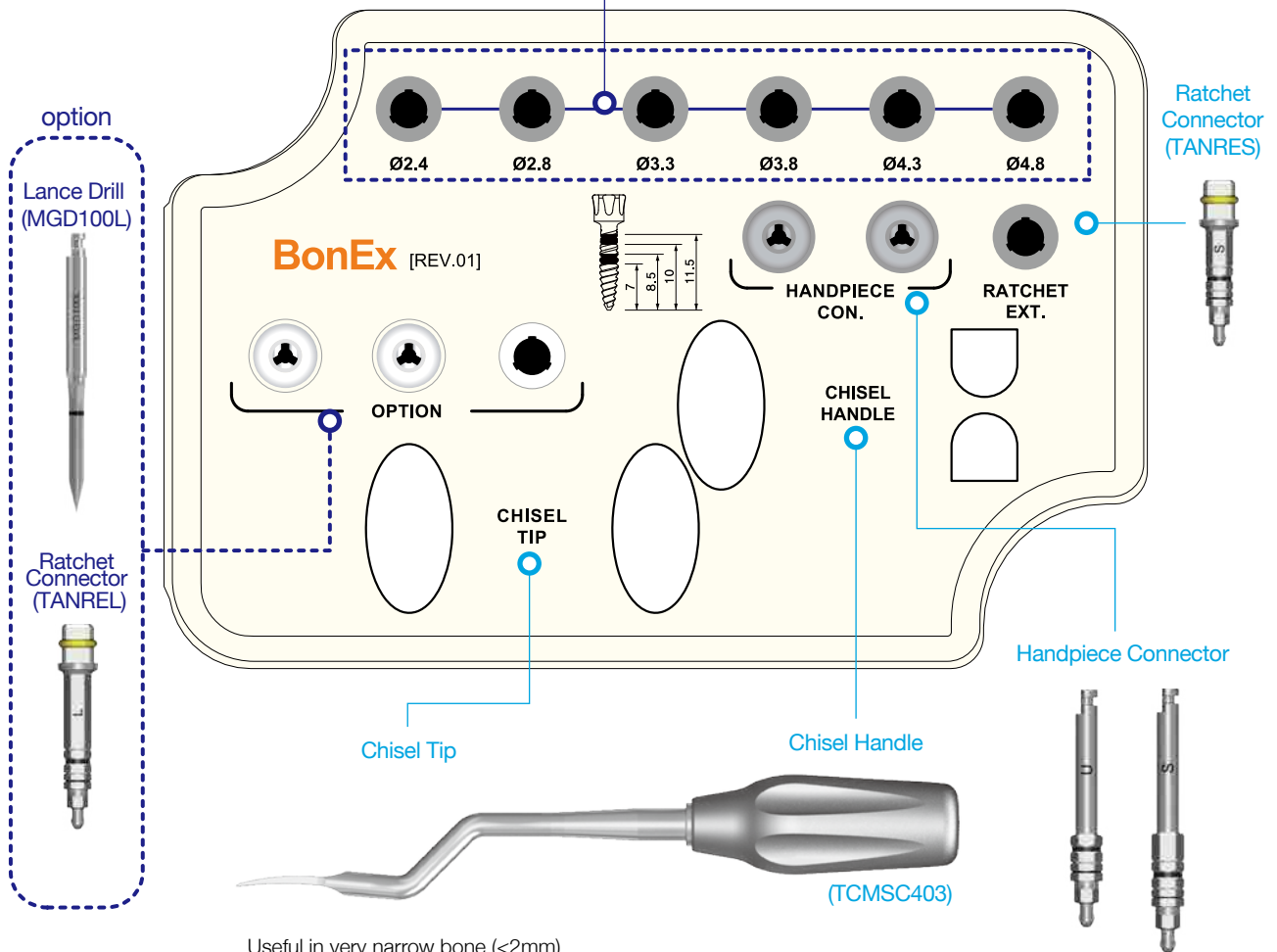
: Best combination with SmartThor™

: Perfect for the exceptionally difficult cases

Description	Diameter	Length (mm)	Marking line(mm)	Ref.C
BonEx Kit	-	-	-	KB ECS3000
BonEx Kit component	Ø2.4	13	7 / 8.5 / 10 / 11.5	TCMBE2413
	Ø2.8			TCMBE2813
	Ø3.3			TCMBE3313
	Ø3.8			TCMBE3813
	Ø4.3			TCMBE4313
	Ø4.8			TCMBE4813

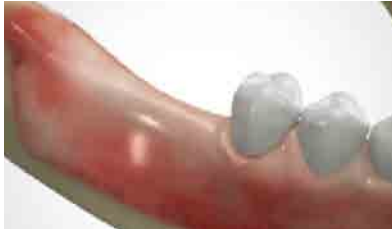

Step-by-step ridge Expander can be placed with a Handpiece & a Ratchet Extension, matching with the core shape of the AnyRidge Fixture .



Useful in very narrow bone (<2mm)
 Use Lance Drill before Expanders to avoid bone breakage during drilling.
 Can be tapped until the end with a Mallet.

► Procedures of Ridge Split Technique



➔ Step 1. Indications

Ridge Splitting techniques may be used in any case with a narrow ridge. Single implant or limited space cases, however, offer less room for expansion.

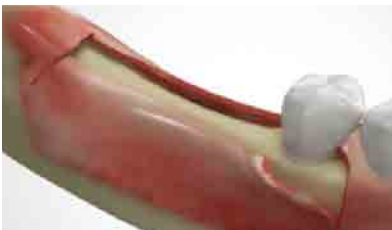If the narrow ridge consists solely of cortical bone with no intervening cancellous bone, it will be difficult to achieve a good ridge split. Also, it is advised to be cautious in the maxillary anterior as ridge splitting may cause the labial cortical bone to move too labially, resulting in severe angulation of the implants.



➔ Step 2. Incision

Incision line is recommended to be at the center of remaining keratinized tissue.

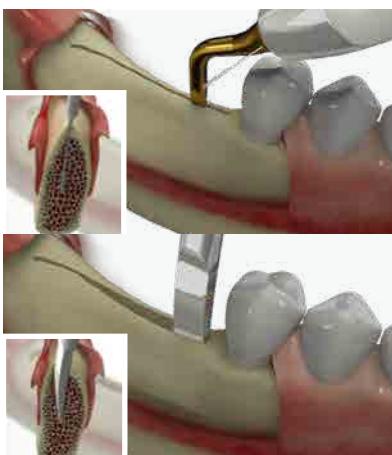A longer horizontal incision is better to permit adequate sawing for ridge splitting. One tooth-size more, mesially and distally.



➔ Step 3. Flap reflection

Full thickness or Full-to-partial thickness flap is recommended.

If the ridge crest is less than 2mm, it is advisable to reduce the crestal bone until the width is at least 2mm.



➔ Step 4. Sawing(with SmarThor)

Sawing starts from the center of ridge.

The ridge should be cut slightly at a buccal angulation, because resorption occurs on buccal bone. If the lingual bone is too thin after sawing, splitting may occur to the lingual side making implant position too far lingual. Thin ridged bone should be cut to the depth of implant length. For example, if the intended implant length is 8.5mm, the incision should be cut to 8.5mm. In most cases, vertical bone cutting is not necessary when you place AnyRidge implant. Only small offsets at the ends of horizontal bone cutting are enough to guide the direction of ridge expansion if needed.

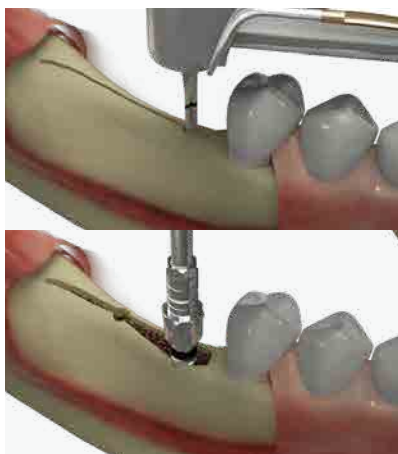
Try to maintain lingual bone thicker than buccal to expand thin ridge buccally.

Slightly angulated cutting is recommended.

Chiseling (Optional)

If the crest is less than 2mm, it's better to expand with a Chisel first.

It is to avoid bone defects which can be made with drilling on the thin ridge. Light tapping with a Mallet will be enough.



➡ Step 5. Drilling

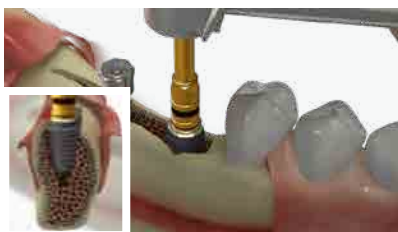Now drill at the desired position and axis of implant.

In ridge expansion technique, lance and 2mm drilling is enough in most cases. It's only to guide the implant path. If a flat-bottomed implant was planned, drilling should be extended to the diameter recommended by the manufacturer, resulting in the dehiscence defect before implant placement.

Expanding with BonEx kit (Optional)

Slow expansion with BonEx Kit is recommended.

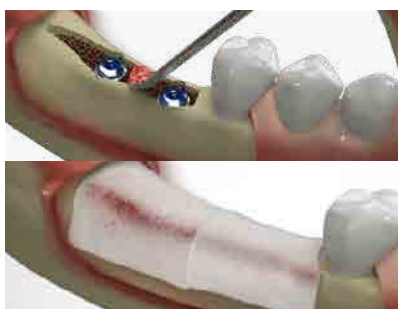
The Expanders can be engaged easily with bone by a handpiece (50 Ncm). If it stops before the depth of osteotomy, use a Torque Wrench or a Ratchet Wrench with Ratchet Extension. Same procedure can be repeated with wider diameter of Expander.



➡ Step 6. Implant placement

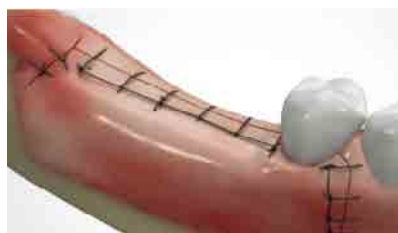Place the implants when the ridge is expanded adequately or has enough flexibility.

If you use Expanders, it's better to leave an Expander during placement of the first implant to keep the ridge expanded. Torque force up to 60-70 Ncm will be fine to place an implant.



➡ Step 7. Bone graft & Membrane

The remaining bone defects can be filled with any kind of bone graft material. Resorbable membrane is recommend for better bone filling.



➡ Step 8. Suture

One stage or two stage approach can be chosen according to the conditions, but it is recommended to finish several cases with a successful result before trying one stage surgical approach.

Adequate periosteal releasing incision is needed if primary closure is planned.

OVER

10 YEARS

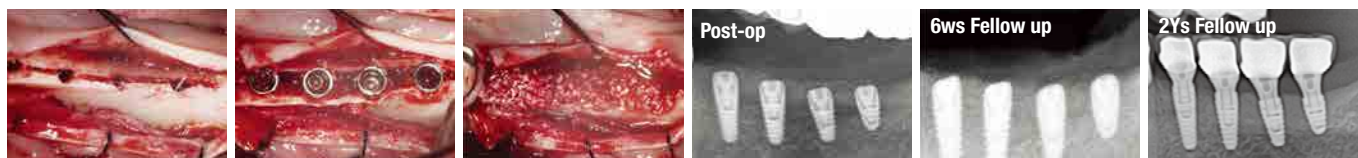The AnyRidge Way

IMPLANT PARADIGM SHIFT SINCE 2009

AnyRidge is Perfect for Ridge Splitting With SmarThor

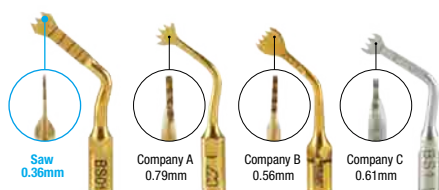
Compare the drilling site with ridge width!

SmarThor & AnyRidge is possible to place wider diameter implant with minimal drilling after ridge splitting even thin ridge under 2mm. It can sure minimally invasive surgery & more efficient result.



Specially Designed Saw for Ridge splitting

Thor's narrow blade enable cutting of super narrow bone crest.



Strong & Easy to use focused on ridge split only piezo

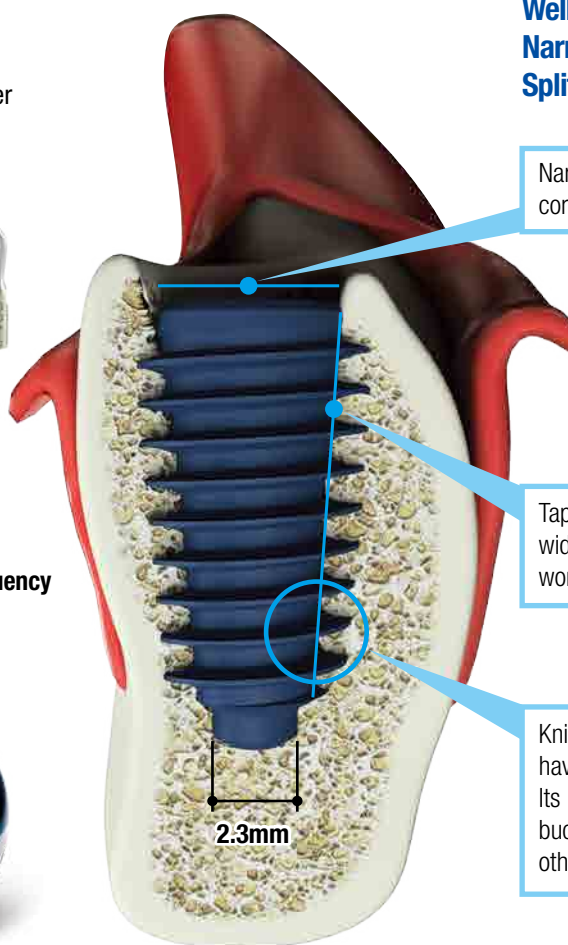
Only Three buttons!

On & Off, Foot switch, Power Boost

Stronger vibration wave & vibration frequency than other piezos.



Well tapered body, Knife Threads, Narrow Platform make Ridge Splitting more effective!



Narrow platform gives no stress to split cortical bone!

Tapered body ensures non-aggressive widening of bone crest because of working as an expander.

Knife Threads make insertion easier, and have an excellent engagement into bone! Its macro shape helps maintain more buccal and lingual cortical bone than any other implant system in the market today.

Have you made the PARADIGM SHIFT yet?

Do it the AnyRidge Way

Excellent primary stability with Knifethread®

- For smooth insertion & stronger primary stability
- No cutting edge for minimal invasion
- Perfect results with any bone condition

Excellent secondary stability with Xpeed®

- Faster & stronger osseointegration
- Surface technology incorporating Ca²⁺ ions on S-L-A treated surface
- 100% acid-residue-free surface



III. Clinical Cases 1 : Mandibular Posterior - *Courtesy of Dr. Kwang-Bum Park*

Fig 1. A 79 year-old female patient visited with a chief complaint of chewing difficulty on the mandibular molar area. She had been using a denture for more than 30 years. The ridge was narrow, which needed an expansion. She was physically healthy. Considering her age, the ridge split technique was decided to be done.

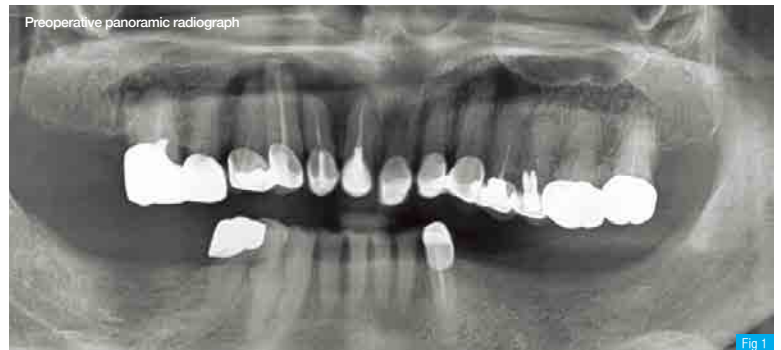

Fig 2. The ridge width was about 3mm on the crest. The ridge was splitted with a thin saw (only horizontally to the depth of implant length) (11.5, 10, 8.5 and 7mm from front to back, respectively), then 2mm lance drilling was done. Compare the drilling site with ridge width.

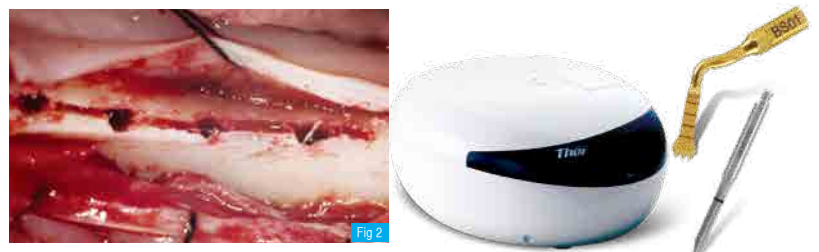

Fig 3. Fixtures were placed with a handpiece which was set on 40 Ncm torque force. Each fixture stopped at the level shown on the picture. Then the fixtures were screwed down with a Torque Wrench, one full turn on each fixture sequentially.

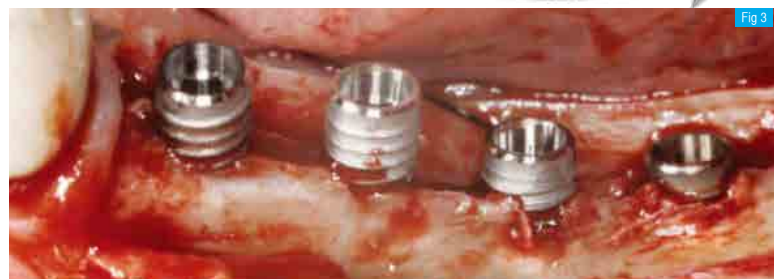

Fig 4. All the fixtures were placed completely, 1 mm under the crest in consideration of bone remodeling. The crestal bone was split enough to make ideal width.

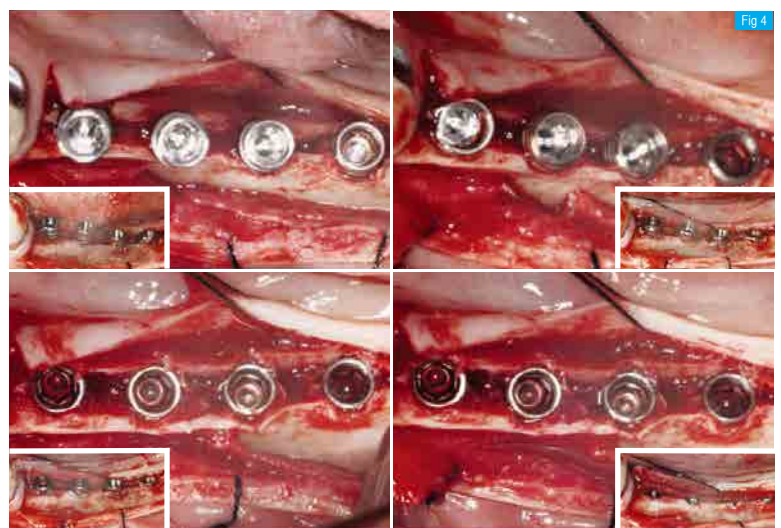


Fig 5. The gap defect was filled with Mega-Oss allograft and covered with a collagen membrane. Then primary closure was made.

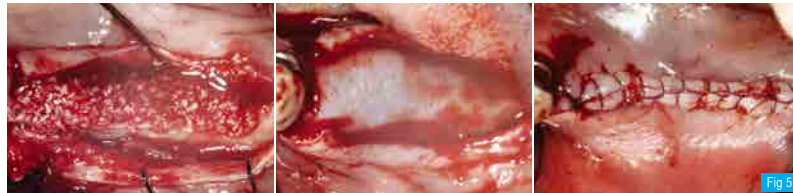

Fig 6 Postoperative panoramic radiograph. The other side was done with same procedure.

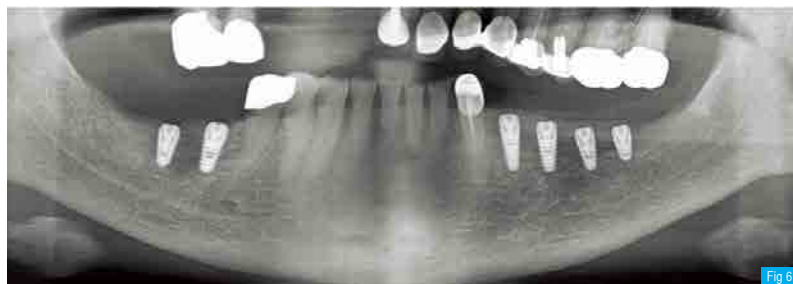


Fig 7. The healing was uneventful, and the second stage surgery was done with simple incision after 3 months.

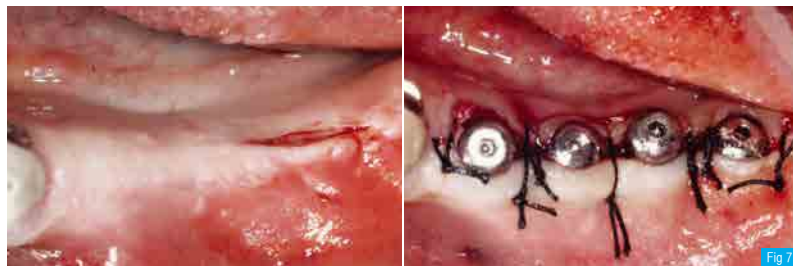
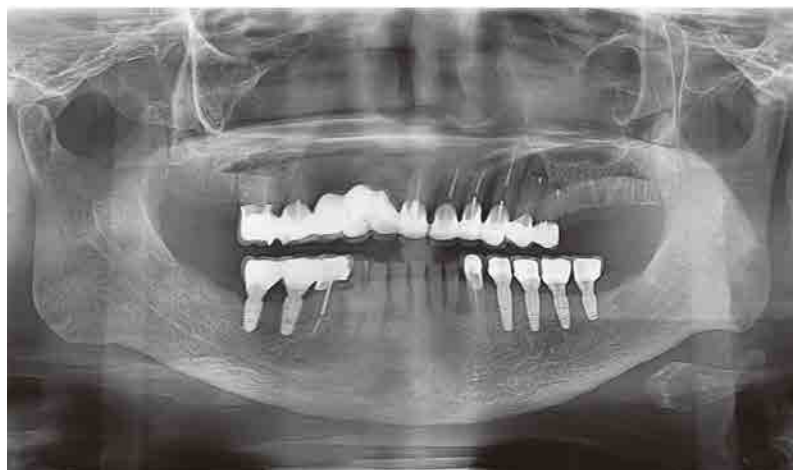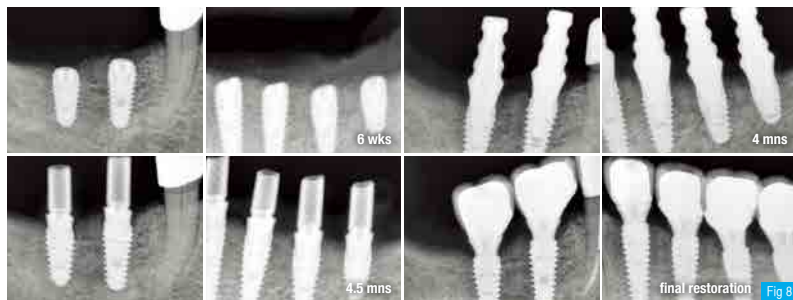


Fig 8. Intraoral radiographs taken at the following procedures. The crestal bone was well maintained with excellent bone regeneration with the ridge split technique.



III. Clinical Cases 2 : Mandibular Posterior - Courtesy of Dr. Kwang-Bum Park

Fig 1. A 74 year-old female patient visited with chief complaints of denture discomfort and chewing difficulty on the mandible. Through the intraoral and radiographic examinations, she showed problems on many teeth, but she wanted to treat edentulous area first. Both mandibular molar area showed thin ridges which needed to be expanded for implant placement.

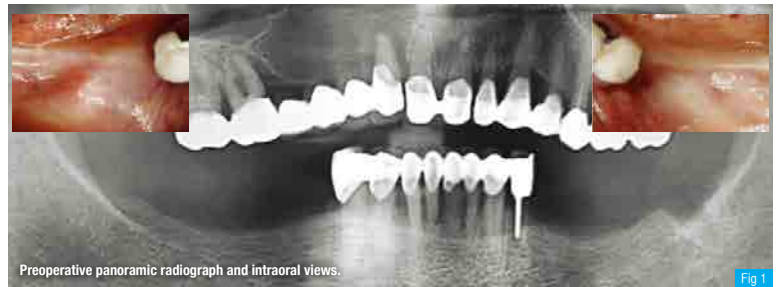

Fig 2. When the flap was reflected on the right side, the ridge width was less than 3mm. The ridge was sawed with a SmarThor horizontally to the depth of 10 mm.

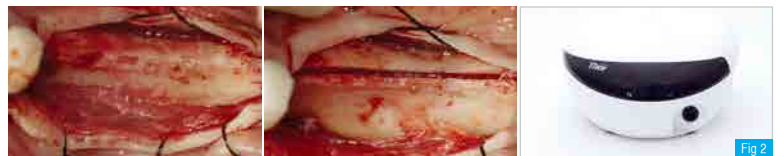

Fig 3. Only hole by Lance Drill (2mm in diameter) was made on the anterior two implant sites, and 2.9mm drilling was done on the second molar area. Then Ø4.5 x 10 mm AnyRidge implants were placed for the two molars. The 50Ncm-set handpiece stopped at the level shown at the center picture. Compare the ridge width and the size of AnyRidge fixtures on the right.

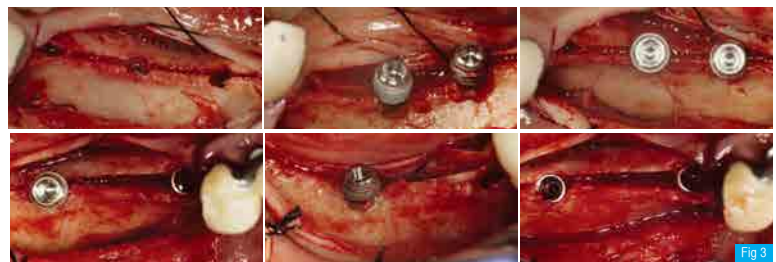


Fig 4. The first molar implant was placed. Due to the special structure of the AnyRidge Implant system, the cortical bone on the top showed greenstick fracture during placement, but when the implant was placed completely under the crest, the fractured bone came back to the original position.



Fig 5. Small amount of Mega-Oss™ allograft and collagen membrane were placed to enhance regeneration, and primary closure was made.

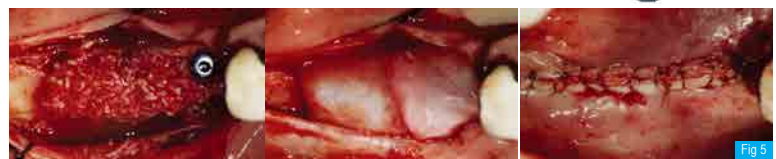

Fig 6. Postoperative panoramic radiograph.

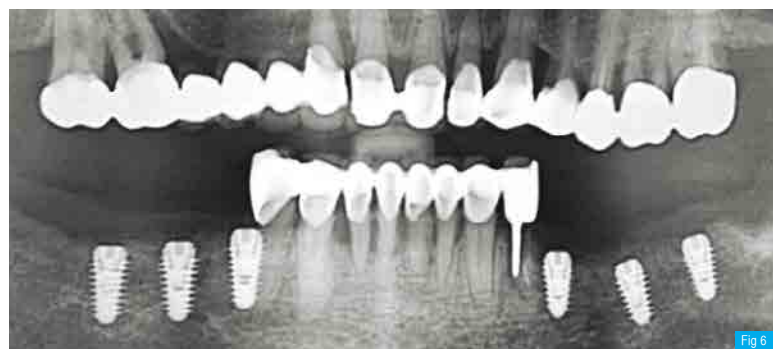


Fig 7. 3 months after the ridge split and implant placement, the second stage surgery was made with simple incision and flap, just by splitting the remaining keratinized tissue into two, despite its being limited. The bone was regenerated excellently.

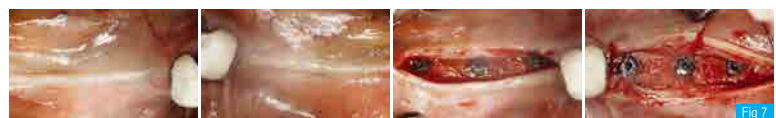

Fig 8. 4mm diameter Healing Abutments were connected. Smaller diameter Healing Abutments were recommended in the case of limited keratinized tissue in order to help preserve the tissue.

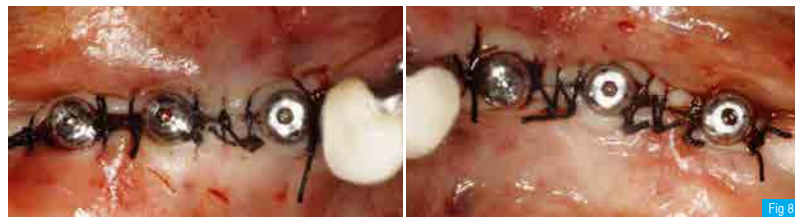

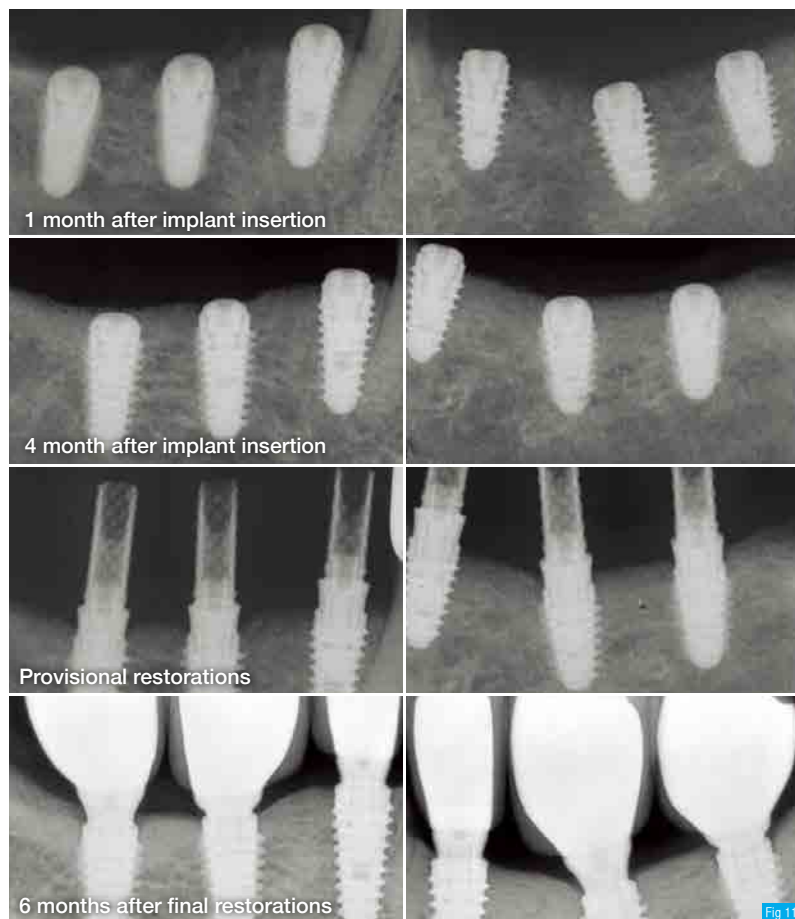
Fig 9. Final restorations were delivered following the routine procedure. All implant prosthetics were made as a single crown.

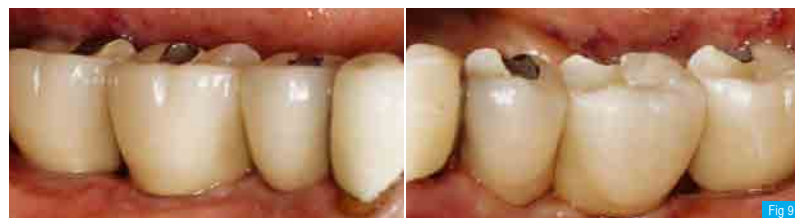

Fig 10. At the first follow-up visit after 3 months from the final restoration delivery, the gingival condition had improved.

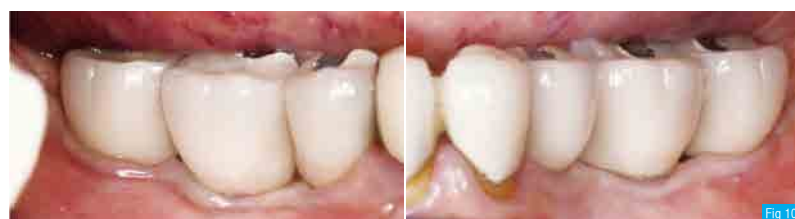

Fig 11. Intra-oral radiographs with clinical procedures and follow-up. All the implants were restored as a single crown. The crestal bone showed excellent response to all implants.



What is the **AnyRidge** way?

For clinicians...

less invasive, fast,
simple, predictable,
& esthetically
superior implant
treatment

Realising the
ONE-DAY Implant™

For patients...

strong new
esthetic &
functional teeth via
painless & rapid
treatment

AnyRidge does it right!

AnyRidge goes FAR BEYOND standard expectations of dental implants...

Key benefits of AnyRidge implants become evident
when considering immediate loading...

With the new loading protocol developed based on
clinical results with AnyRidge, your patients have
new smiles faster than ever....

- Guaranteed excellent stability, even with compromised bone density
- Less reduction & more preservation of cortical bone
- Wider implant possibilities than crestal width
- Clinically proven safety
- Faster & stronger osseointegration
- Esthetic design & varied abutment selection
- Super implant-prosthetic connection
- Innovative R2GATE software for completing implant & prosthesis in ONE DAY



Narrow Ridge



Head Office & Factory
Gangnam Office

45, Secheon-ro 7-gil, Dasa-eup, Dalseong-gun, Daegu, Korea
MegaGen Tower, 607 Seolleung-ro, Gangnam-gu, Seoul, Korea

T. +82-1544-2285
T. +82-1566-2338