

# Surgical Accuracy of Positioning the Maxilla in Patients With Skeletal Class II Malocclusion Using Computer-Aided Design and Computer-Aided Manufacturing-Assisted Orthognathic Surgery

Ali Alqussair, DDS,\* Seung-Hak Baek, DDS, PhD,† Tae-Seup Kim, DDS, MSD,‡  
Sugn-Ho Ha, DDS, PhD,‡ and Jin-Young Choi, DDS, MD‡

**Objective:** To evaluate the surgical accuracy of positioning the maxilla in patients with skeletal class II malocclusion using computer-aided design and computer-aided manufacturing (CAD/CAM)-assisted orthognathic surgery.

**Materials and Methods:** The samples consisted of 10 patients with skeletal class II malocclusion, whose cone-beam computed tomographs taken before and immediately after surgery were available and who underwent bimaxillary orthognathic surgery by a single surgeon using Le Fort I osteotomy and bilateral sagittal split ramus osteotomy at the Department of Oral and Maxillofacial Surgery, Seoul National University Dental Hospital, Seoul, South Korea between January 2018 and December 2019. After virtual surgical planning was performed using the FACEGIDE system (Korea), surgical cutting guides, intermediate splints, and custom-made titanium mini-plates were fabricated using CAD/CAM technique. Using 8 landmarks (anterior nasal spine, point A, #16, #13, contact point between #11 and #21, #23, #26, posterior nasal spine), the mean differences between the virtually planned (Virtual) and actual postsurgical position of the maxilla (Actual) in the three-dimensional coordinates ( $\Delta$ Actual-Virtual) and their mean absolute deviations were investigated.

**Results:** The mean differences of 8 landmarks were 0.42 mm left side movement in the transverse coordinate, 0.15 mm forward movement in the sagittal coordinate and 0.10 mm downward movement in the vertical coordinate. Their mean absolute deviations were 0.98, 0.67, and 0.62 mm in the sagittal, vertical, and transverse coordinates, respectively.

**Conclusions:** Since the mean difference was less than 0.5 mm and the range of error was less than 1.0 mm, CAD/CAM-assisted orthognathic surgery might have a high degree of surgical accuracy and clinical relevance in the positioning of the maxilla.

**Key Words:** CAD/CAM technology, skeletal class II, surgical accuracy

(*J Craniofac Surg* 2022;33: 1479–1483)

The success of orthognathic surgery is dependent on good surgical technique as well as accurate surgical planning.<sup>1</sup> Conventional surgical planning of orthognathic surgery consists of cephalometric analysis, mock surgery, face-bow transfer, bite wax recording, mounting of models into a semi-adjustable articulator, and model surgery.<sup>1–4</sup> Although all these steps may lead to errors in surgical planning, there are several other sources of incorporating errors as follows: inaccurate transfer of the occlusal plane, discrepancies in natural head position, differences between the hinge axis and condylar rotation when making the wafers, complicated and inaccurate measurements of the lines traced on the rough surfaces of the plaster casts, absence of soft-tissue parameters, difficulty in diagnosis of occlusal cant and asymmetry of the facial skeleton.<sup>5–9</sup> The development of computer-aided design and computer-aided manufacturing (CAD/CAM) technique, which represents a paradigm shift in surgical planning for orthognathic surgery, can allow surgeons to overcome most of the above-mentioned limitations.<sup>10</sup>

Virtual planning offers several advantages compared to conventional planning,<sup>1</sup> including: (1) A diagnostic evaluation performed on a three-dimensional (3D) virtual model; this diagnostic tool makes it possible to detect and quantify dental cant, yaw deformities, and other facial asymmetries. (2) 3D virtual planning provides the surgeon with the freedom to simulate different surgical procedures to obtain the best possible outcome for the patient. (3) 3D virtual planning facilitates the evaluation and correction of centric relation (CR) in the temporomandibular joint (TMJ). (4) Computer-aided design and computer-aided manufacturing technology has made an increase in the predictability of orthognathic surgeries possible. Nevertheless, achieving a high level of accuracy remains a major challenge for surgeons.<sup>5,11,12</sup>

From the \*Department of Oral and Maxillofacial Surgery, Dammam Medical Complex, Ministry of Health in Saudi Arabia in a Training Program at the Department of Oral and Maxillofacial Surgery, Dental Hospital; †Department of Orthodontics; and ‡Department of Oral and Maxillofacial Surgery, School of Dentistry, Seoul National University, Seoul, South Korea.

Received October 31, 2021.

Accepted for publication November 4, 2021.

Address correspondence and reprint requests to Jin-Young Choi, DDS, MD, Department of Oral and Maxillofacial Surgery, School of Dentistry, Dental Research Institute, Seoul National University, Daehak-ro #101, Jongno-gu, Seoul 03080, South Korea; E-mail: jinychoi@snu.ac.kr

Ethical approval for this study was not required as no human subject data was included.

The authors report no conflicts of interest.

Supplemental digital contents are available for this article. Direct URL citations appear in the printed text and are provided in the HTML and PDF versions of this article on the journal's Web site (www.jcraniofacialsurgery.com).

Copyright © 2021 by Mutaz B. Habal, MD

ISSN: 1049-2275

DOI: 10.1097/SCS.00000000000008407

In previous studies, a difference was noted between planned and actual maxilla position were found and this may be related to imperfect condylar seating, which significantly affects mandibular positioning during surgery, even with classical planning.<sup>8,13</sup> Condylar seating significantly affects mandibular positioning and remains a source of inaccuracy during surgery, which leads to incorrect positioning of the maxilla. Insufficient seating of the condylar segments may have caused unintentional changes to the surgical plan, causing an under-advancement of the jaws.<sup>14</sup>

Patients with skeletal class II malocclusions, when in the physiological rest position, place the mandible in a more protrusive position than patients with class I occlusion.<sup>15-17</sup> Deng et al<sup>18</sup> showed a positive rate of centric relation-centric occlusion (CO) discrepancy as 92.5% (74 cases) in the group of Angle class II malocclusion and 10.0% (5 cases) in the group of normal occlusions (*P* < 0.001). When patients with class II malocclusions are treated, difficulties may arise as a result of the difference between CR and the habitual position.<sup>19-21</sup> As accurate positioning of the maxilla is affected by condylar seating and class II patients have significantly higher CR-CO discrepancy we chose this group of patients for our study.

After looking over published literature, we found only 1 study taking concern on class II malocclusion by evaluating the postsurgical stability performing a counter-clockwise rotational procedure for the maxilla-mandibular complex.<sup>22</sup> As did not clearly show the postoperative accuracy we decided to continue to do our evaluation.<sup>22</sup>

Our retrospective cohort study aimed to evaluate the surgical accuracy of positioning the maxilla in patients with skeletal class II malocclusion using CAD/CAM-assisted orthognathic surgery.

## MATERIALS AND METHODS

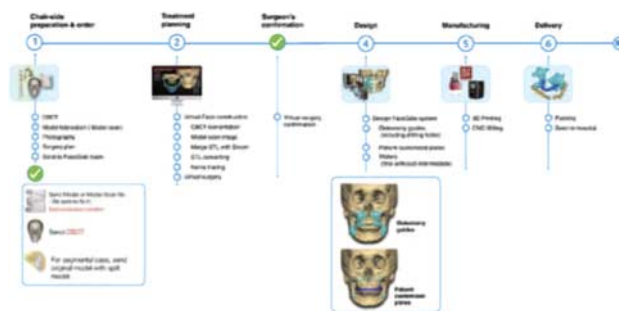
### Subjects

The samples consisted of 10 patients (4 male and 6 female) with skeletal class II malocclusion. The median age was 29.3 years, with the youngest 20 years old and the oldest was 44 years old. All these patients underwent bimaxillary orthognathic surgery by a single surgeon using Le Fort I osteotomy and bilateral sagittal split ramus osteotomy at the Department of Oral and Maxillofacial Surgery, Seoul National University Dental Hospital, Seoul, South Korea between January 2018 and December 2019. The exclusion criteria were (1) patients who had temporomandibular ankylosis or artificial TMJ, (2) patients who had a history of orthognathic surgery, and (3) patients who had a history of facial bone trauma, tumors, or cleft lip and/or palate. There were no cases of facial asymmetry. This retrospective study was reviewed and approved by the Institutional Review Board (IRB) of the Seoul National University Dental Hospital, Seoul, Republic of Korea (IRB number ERI20031).

### Virtual Surgical Planning and Orthognathic Surgical Procedures

After cone-beam computed tomography was taken just before surgery and after presurgical orthodontic treatment, the facial skeleton and soft tissues were digitally recreated using digital imaging and communications in medicine (DICOM) data. Then the digital imaging and communications in medicine files were converted into stereolithography so that the patient's 3D skull was generated. The occlusal plaster models were scanned for the incorporation of dental arches of the maxilla and mandible into the virtual skull.

With help of 3D and clinical measurements, the virtual surgical planning was performed by moving and rotating the jaw segments



**FIGURE 1.** The workflow of CAD/CAM-assisted orthognathic surgery using the FACEGIDE system (Megagen implant system, Korea). CAD/CAM, computer-aided design and computer-aided manufacturing.

with the FACEGIDE system (Megagen implant, Daegu, South Korea, Fig. 1). Among 10 patients, segmentation of the maxilla into 2 fragments was performed in 3 patients. Then, surgical cutting guides, intermediate splints, and custom-made titanium mini-plates were fabricated using CAD/CAM technique (Fig. 2).

The maxilla surgery was the first performed on all 10 patients. The vertical dimension of the maxilla and the position of the chin segment were established with intraoperative clinical measurements. The maxilla was fixed with 4 customized titanium mini-plates and the mandible was fixed with 2 4-hole customized titanium miniplate.

### Recreation of Actual Postsurgical Three-Dimensional Model

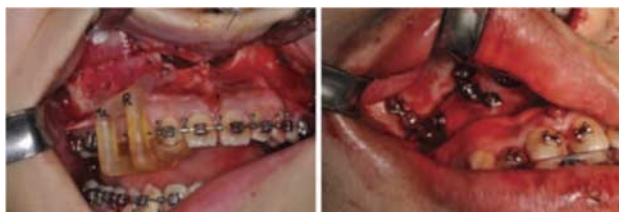An actual postsurgical 3D model was recreated from postoperative cone-beam computed tomography taken immediately after surgery (3rd–5th postoperative days). The reason was to avoid possible positional or adaptive relapse or resorption or remodeling of the TMJ.

### Registration of the Maxilla Between Virtually Planned and Actual Postsurgical Three-Dimensional Models

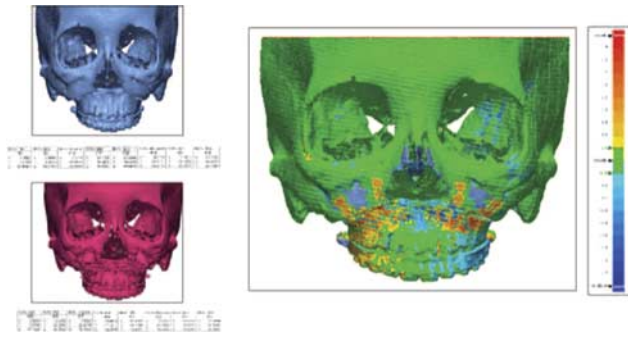
The actual postsurgical 3D model was rendered and registered to the preoperative virtually planned 3D model using the structures unaffected by surgery (anterior cranial base, zygomatic arches, and forehead).

### Parameters for Translational Movements of the Maxilla to Evaluate the Surgical Accuracy

Using 8 landmarks (anterior nasal spine, posterior nasal spine, point A, #16, #13, contact point between #11 and #21, #23, #26), which are explained in Supplementary Digital Content, Table 1, <http://links.lww.com/SCS/D611>, the mean difference between the virtually planned (Virtual) and actual postsurgical position (Actual) of the maxilla in the



**FIGURE 2.** (A) Example of surgical cutting guide placed on the occlusal surface of the maxillary teeth, (B) Example of customized titanium plate after fixation of the maxilla.



**FIGURE 3.** (A) Virtually planned position of the maxilla; (B) Actual postsurgical position of the maxilla; (C) Actual-Virtual, Superimposition model of virtually planned maxilla with actual maxilla position.

3D-coordinates ( $\Delta$ Actual-Virtual in the sagittal, transverse, and vertical coordinates) were calculated to measure the surgical accuracy of positioning the maxilla in terms of the vector. A positive value means that the maxilla was displaced forward, upward, or to the right side. A negative value means that the maxilla was displaced backward, downward, or to the left side. A mean difference less than 1 mm was considered as accurate and accuracy rate was calculated by number of accurate movements divided by number of all movement multiplied by 100. Examples of the virtually planned and actual postsurgical 3D models and their superimposition are shown in Figure 3. Besides, the mean of absolute deviation was calculated to see how much the range of error was possible in the 3D-coordinates.

**RESULTS**

All the surgeries were completed successfully using our FACEGIDE system. All the patients achieved good final occlusion with postoperative elastic traction. There was no sign of abnormal bleeding, breakage of the custom plates, or any difficulty in using the FACEGIDE system.

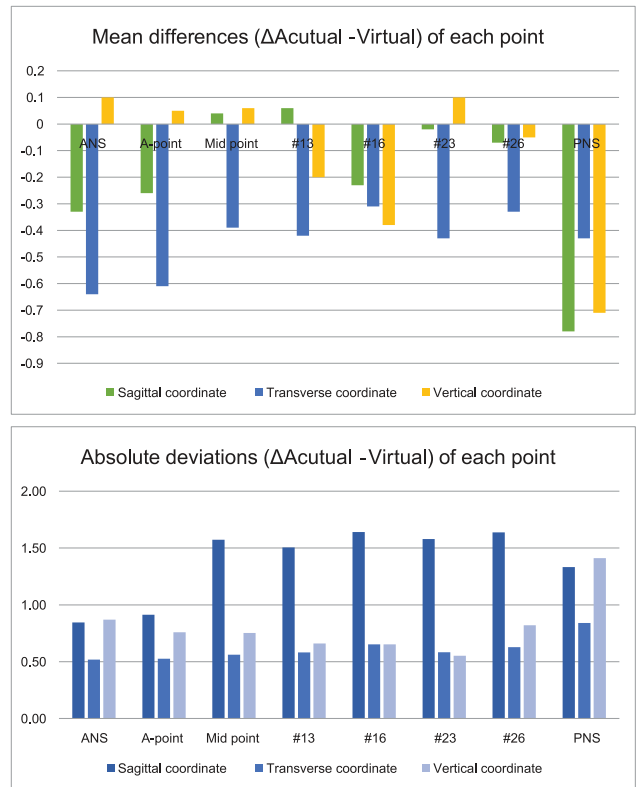
The mean differences of 8 landmarks between the virtually planned and actual postsurgical position of the maxilla in the 3D-coordinates ( $\Delta$ Actual-Virtual) were 0.42 mm left side movement in the transverse coordinate (X), 0.15 mm forward movement in the sagittal coordinate (Z), and 0.10 mm downward movement in the vertical coordinate (Y), in descending order (Supplementary Digital Content, Table 2, <http://links.lww.com/SCS/D612>). These values indicated the CAD/CAM-assisted orthognathic surgery might have a high degree of surgical accuracy of positioning the maxilla in patients with skeletal class II malocclusion.

Their mean absolute deviations were 0.88 mm in the sagittal coordinate (Z), 0.67 mm in the vertical coordinate (Y), and 0.62 mm in the transverse coordinate (X), in descending order (Supplementary Digital Content, Table 2, <http://links.lww.com/SCS/D612>). Since the range of error was less than 1 mm in the 3D-coordinates, it can be stated the CAD/CAM-assisted orthognathic surgery might have clinical relevance.

The mean differences and absolute deviations of each point in all patients are labeled in Figure 4.

**DISCUSSION**

In a previous study by Choi et al, to find out the precise accuracy rate according to the surgical movement type of the maxilla maxillary setback showed a tendency toward lower accuracy and overcorrection than maxillary advancement.<sup>23</sup> Also, the maxillary impaction showed a tendency toward lower accuracy and overcorrection than the maxillary elongation.



**FIGURE 4.** (A) Chart labels the mean differences between the predicted and actual postsurgical position of the maxilla in the 3D-coordinates ( $\Delta$ Actual-Virtual) of each point. A positive value means that the maxilla was displaced forward, upward, or to the right side. A negative value means that the maxilla was displaced backward, downward, or to the left side, (B) Chart labels the absolute deviations between the predicted and actual postsurgical position of the maxilla in the 3D-coordinates ( $\Delta$ Actual-Virtual) of each point. 3D, three-dimensional.

These findings mean that precise control of the backward and upward movements, which are the most applied in class II orthognathic surgery, of the maxilla was more difficult than the forward and downward movements.

Previously conducted studies evaluated the accuracy of Le Fort I maxillary osteotomy using conventionally planned surgeries with respect to the presurgical prediction.<sup>24-6</sup> The accuracy of their conventionally planned surgeries was lower than that found in our investigation, including 43%,<sup>25</sup> 26%,<sup>26</sup> and 20%<sup>24</sup> were within 1 mm of the predicted position. Although in our study, 74% within 1 mm of prediction. By comparing these we can confirm that a 3D planned orthognathic surgery is more accurate than conventionally planned ones.

Furthermore, other studies were done to evaluate the accuracy of maxilla positioning using 3D printed wafer only without using 3D surgical guides or customized osteosynthesis plates.<sup>14,27-29</sup> They reported the mean of linear difference in the 3 axes as: X (0.1 ± 0.7 mm), Y (-0.6 ± 1.3 mm), and Z (-0.5 ± 1.3 mm), X (-0.31 ± 1.41 mm), Y (-0.05 ± 1.37 mm),<sup>29</sup> and Z (-0.39 ± 2.38 mm),<sup>14</sup> X(-0.46 mm), Y (-0.45 mm), and Z (0.29 mm).<sup>27</sup> As we see even wafer-only controlled surgeries had relatively accurate results but as Mulier et al<sup>29</sup> said that the inter-maxillary wafer only controls surgical movements in the sagittal and transverse plane, the vertical maxillary repositioning is more challenging. However, looking at the values of the Z axis evaluation in these studies, the average value shows a low value, but the error range is much larger. This is thought to be because condyle positioning during

surgery is not easy because class II malocclusion patients have a tendency to CO-CR discrepancy. However, in our study, by double checking using 3D printed wafer and customized plate, not only the mean error in the Z axis of the maxillary segment was small, but the error range was also much smaller than that reported in previous studies. Therefore, the application of 3D-printed surgical guides and patient-specific osteosynthesis plates could improve the limitations encountered with the wafer only technique. Accuracy correlated negatively with increased surgical complexity, particularly posterior differential impactions of the maxilla.<sup>24</sup> Furthermore, in skeletal class II patients after performing a counter-clockwise rotational procedure, it showed that the maxilla also had a clockwise rotation tendency.<sup>22</sup>

In order to eliminate any sort of additional devices for positioning of the maxilla, some authors did their study on 3D surgical guides and customized osteosynthesis plates but excluded the use of intermaxillary wafer.<sup>30</sup> Brunso et al reached 71.2% of the postoperative bone surface within 1 mm for the maxilla. Where is showed 84.09% of discrepancies being below 1 mm.<sup>31</sup> However, Li et al reported mean differences in the maxillary dental arch midline ( $0.32 \pm 0.34$  mm),<sup>30</sup> Heufelder et al reported the absolute mean difference in the 3 axes: X ( $0.30 \pm 0.95$  mm), Y ( $0.33 \pm 1.22$  mm), and Z ( $0.72 \pm 2.0$  mm).<sup>32</sup> Although in our study, we reached 74% within 1 mm of prediction of the mean differences in the 3 axes: X ( $0.42 \pm 0.62$  mm), Y ( $0.10 \pm 0.67$  mm), and Z ( $0.15 \pm 0.88$  mm). In addition to these, in a previous study by Kim et al, which used the same system (FACEGIDE) as we are, the mean distance difference at all reference points between Tv and T1 was ( $1.01 \pm 0.3$  mm).<sup>33</sup> As we reached similarly high accuracy and had a narrower range of error, this means that these findings suggested more acceptable accuracy of the transfer of the virtual planning event to the skeletal class II patients.

The cutting guides, used in our study, were easy to position and rarely have a poor adaptation to the bone surface. This allowed correct and accurate osteotomy and facilitates bone repositioning. The use of bone-surface guides and 1 arm on the cusp of the teeth, improved their stability as mentioned in other studies.<sup>34,35</sup> Moreover, the predetermination of screw hole locations allows the choice of the thickest bone to achieve greater screw locking and the passive adaptation and stability of the customized fixation plates.<sup>33</sup> Surgical time is reduced since there is no need to bend plate or do intraoperative measures to check bone repositioning as stated by others.<sup>11,32</sup>

As there is great variability in the techniques used in the precision evaluation methods and the data presented by different studies, in our study, the accuracy was evaluated through linear analysis, so that the discrepancies between the virtual and postoperative planning models were evaluated three-dimensionally, in the 3 axes of movement of the maxilla, X (transverse coordinate), and Y (vertical coordinate), and Z (sagittal coordinate), following a standardization recommendation proposed by Gaber et al (2017) for assessments of surgical accuracy.

## CONCLUSIONS

Since the mean difference was less than 0.5 mm and the range of error was less than 1.0 mm, CAD/CAM-assisted orthognathic surgery might have a high degree of surgical accuracy and clinical relevance in the positioning of the maxilla even in patients with skeletal class II malocclusion.

## REFERENCES

1. Stokbro K, Aagaard E, Torkov P, et al. Virtual planning in orthognathic surgery. *Int J Oral Maxillofac Surg* 2014;43:957–965

2. Bailey JO Jr., Nowlin TP. Evaluation of the third point of reference for mounting maxillary casts on the Hanau articulator. *J Prosthet Dent* 1984;51:199–201
3. Bamber MA, Firouzal R, Harris M, et al. A comparative study of two arbitrary face-bow transfer systems for orthognathic surgery planning. *Int J Oral Maxillofac Surg* 1996;25:339–343
4. Bowley JF, Michaels GC, Lai TW, et al. Reliability of a facebow transfer procedure. *J Prosthet Dent* 1992;67:491–498
5. Aboul-Hosn Centenero S, Hernández-Alfaro F. 3D planning in orthognathic surgery: CAD/CAM surgical splints and prediction of the soft and hard tissues results – our experience in 16 cases. *J Craniomaxillofac Surg* 2012;40:162–168
6. Ellis E III, Tharanon W, Gambrell K. Accuracy of face-bow transfer: effect on surgical prediction and postsurgical result. *J Oral Maxillofac Surg* 1992;50:562–567
7. Gateno J, Forrest KK, Camp B. A comparison of 3 methods of face-bow transfer recording: implications for orthognathic surgery. *J Oral Maxillofac Surg* 2001;59:635–640
8. Sharifi A, Jones R, Ayoub A, et al. How accurate is model planning for orthognathic surgery? *Int J Oral Maxillofac Surg* 2008;37:1089–1093
9. Zizelmann C, Hammer B, Gellrich NC, et al. An evaluation of face-bow transfer for the planning of orthognathic surgery. *J Oral Maxillofac Surg* 2012;70:1944–1950
10. Zinser MJ, Mischkowski RA, Sailer HF, et al. Computer-assisted orthognathic surgery: feasibility study using multiple CAD/CAM surgical splints. *Oral Surg Oral Med Oral Pathol Oral Radiol* 2012;113:673–687
11. Brunso J, Franco M, Constantinescu T, et al. Custom-machined miniplates and bone-supported guides for orthognathic surgery: a new surgical procedure. *J Oral Maxillofac Surg* 2016;74:1061.e1–1061.e12
12. Song KG, Baek SH. Comparison of the accuracy of the three-dimensional virtual method and the conventional manual method for model surgery and intermediate wafer fabrication. *Oral Surg Oral Med Oral Pathol Oral Radiol Endod* 2009;107:13–21
13. Helkimo M, Ingervall B, Carlsson GE. Variation of retruded and muscular position of mandible under different recording conditions. *Acta Odontol Scand* 1971;29:423–437
14. Stokbro K, Aagaard E, Torkov P, et al. Surgical accuracy of three-dimensional virtual planning: a pilot study of bimaxillary orthognathic procedures including maxillary segmentation. *Int J Oral Maxillofac Surg* 2016;45:8–18
15. Curtis TA, Langer Y, Curtis DA, et al. Occlusal considerations for partially or completely edentulous skeletal class II patients. Part I: background information. *J Prosthet Dent* 1988;60:202–211
16. Lowe AA, Takada K, Taylor LM. Muscle activity during function and its correlation with craniofacial morphology in a sample of subjects with class II, division 1 malocclusions. *Am J Orthod* 1983;84:204–211
17. Parr GR, Ivanhoe JR. Lingualized occlusion: an occlusion for all reasons. *Dent Clin North Am* 1996;40:103–112
18. Deng X, Wan Z, He SS, et al. The centric relation-maximum intercuspation discrepancy in adult angle's class II pretreatment patients. *Hua Xi Kou Qiang Yi Xue Za Zhi* 2011;29:48–52
19. Afzal A, Shameem A. Comparison of condylar positions in centric relation and centric occlusion in pre-treatment malocclusion cases. *J Coll Physicians Surg Pak* 2005;15:620–623
20. Ambard A, Mueninghoff L. Planning restorative treatment for patients with severe Class II malocclusions. *J Prosthet Dent* 2002;88:200–207
21. Parreiras Ferreira R, Isaias Seraidarian P, Santos Silveira G, et al. How a discrepancy between centric relation and maximum intercuspation alters cephalometric and condylar measurements. *Compend Contin Educ Dent* 2020;41:e1–e6
22. Wan Z, Shen SG, Gui H, et al. Evaluation of the postoperative stability of a counter-clockwise rotation technique for skeletal class II patients by using a novel three-dimensional position-posture method. *Sci Rep* 2019;9:13196
23. Choi JY, Choi JP, Baek SH. Surgical accuracy of maxillary repositioning according to type of surgical movement in two-jaw surgery. *Angle Orthod* 2009;79:306–311

24. Abela S, Tewson D, Prince S, et al. Precision of Le Fort I osteotomy: planning versus outcome. A multi-centre retrospective study. *J Orthod* 2017;44:8–13
25. Jacobson R, Sarver DM. The predictability of maxillary repositioning in LeFort I orthognathic surgery. *Am J Orthod Dentofacial Orthop* 2002;122:142–154
26. Semaan S, Goonewardene MS. Accuracy of a LeFort I maxillary osteotomy. *Angle Orthod* 2005;75:964–973
27. Baan F, Liebrechts J, Xi T, et al. A new 3D tool for assessing the accuracy of bimaxillary surgery: the Ortho Gnathic Analyser. *PLoS One* 2016;11:e0149625
28. Hsu SS-P, Gateno J, Bell RB, et al. Accuracy of a computer-aided surgical simulation protocol for orthognathic surgery: a prospective multicenter study. *J Oral Maxillofac Surg* 2013;71:128–142
29. Mulier D, Shaheen E, Shujaat S, et al. How accurate is digital-assisted Le Fort I maxillary osteotomy? A three-dimensional perspective. *Int J Oral Maxillofac Surg* 2020;49:69–74
30. Li B, Shen S, Jiang W, et al. A new approach of splint-less orthognathic surgery using a personalized orthognathic surgical guide system: a preliminary study. *Int J Oral Maxillofac Surg* 2017;46:1298–1305
31. Monteiro Carneiro NC, Oliveira DV, Real FH, et al. A new model of customized maxillary guide for orthognathic surgery: precision analysis. *Craniomaxillofac Surg* 2020;48:1119–1125
32. Heufelder M, Wilde F, Pietzka S, et al. Clinical accuracy of waferless maxillary positioning using customized surgical guides and patient specific osteosynthesis in bimaxillary orthognathic surgery. *J Craniomaxillofac Surg* 2017;45:1578–1585
33. Huang SF, Lo LJ, Lin CL. Biomechanical optimization of a custom-made positioning and fixing bone plate for Le Fort I osteotomy by finite element analysis. *Comput Biol Med* 2016;68:49–56
34. Brunso J, Prol C, Franco M, et al. Customised guides and mini-plates: a guided-protocol for orthognathic surgery. *Revista Española de Cirugía Oral y Maxilofacial* 2017;39:7–14
35. Kim JW, Kim JC, Jeong CG, et al. The accuracy and stability of the maxillary position after orthognathic surgery using a novel computer-aided surgical simulation system. *BMC Oral Health* 2019;19:18

