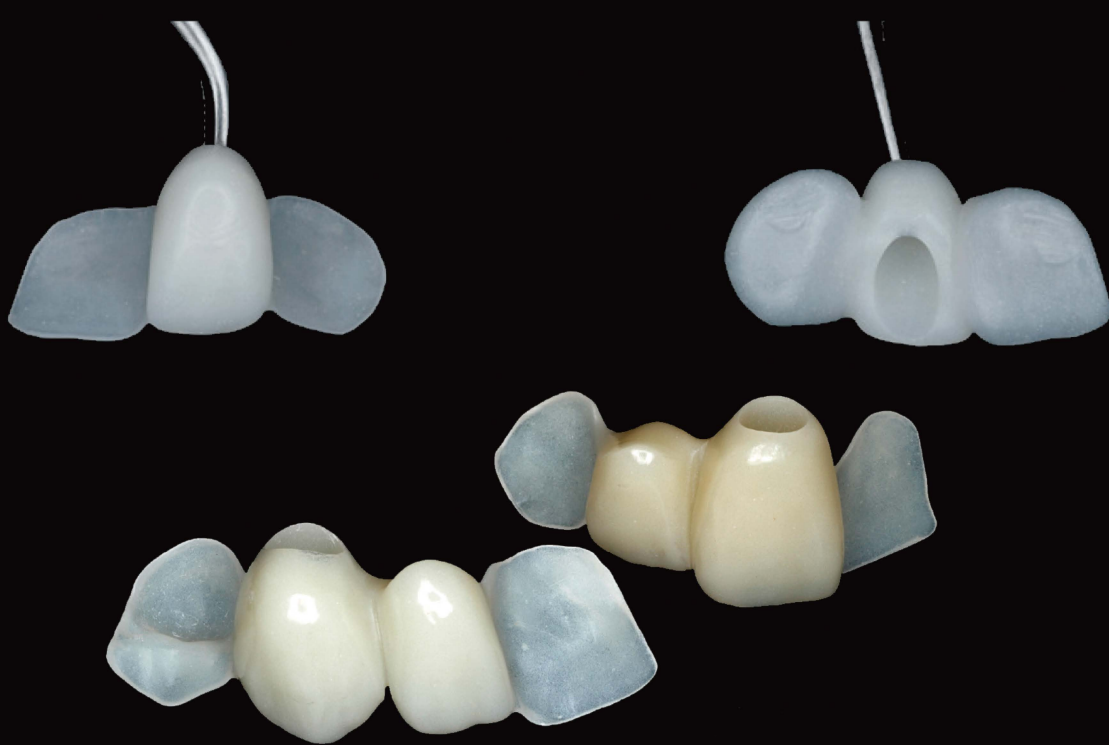



# Digitally Planned Temporization of Implants in the Esthetic Zone with Custom Shell

Dr. Dmitriy Ivanov, DDS



QR video clip  
Welcome message  
fro't\_°r. Dmitriy 15'1ov

## Abstract

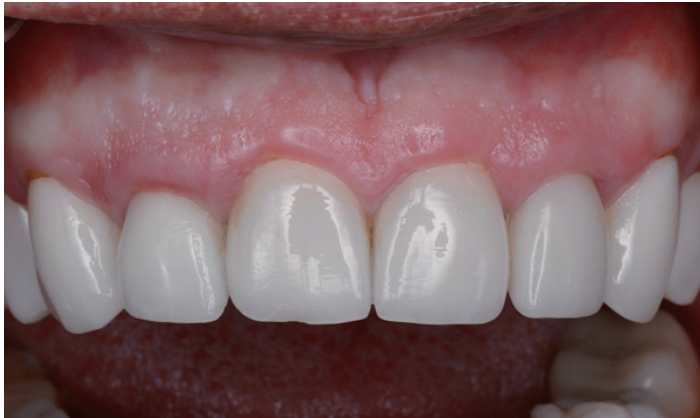Implants in the esthetic zone represent one of the most challenging clinical situations. The esthetic zone requires a comprehensive approach between surgical and prosthetic counterparts. Soft tissue management surgically as well as restorative tissue conditioning play a paramount role in the ability to achieve successful long-term results, both functionally and esthetically. With advances in digital dentistry, we are capable of more predictable planning of implant restoration in more precise and efficient way both surgically and prosthetically. Immediacy in implant dentistry has become THE norm in many aspects of treatment from a single tooth to a full-mouth rehabilitation. Immediate implantology and a non-functional immediate temporization of implants allow us to give patients an immediate esthetic result as well as a shorter treatment time.

This clinical report will discuss multiple aspects implantology in the esthetic zone with great emphasis on digitally planned temporization of immediate or delayed implants with customization of the emergence profile chairside using a lab-made custom shell.

Implant temporization at the time of tooth removal allows for the preservation of soft tissue to replicate the natural tooth emergence, papilla and gingival zenith support (case 1), whereas temporization of delayed implants is done to re-establish the soft tissue emergence and contours prior to the final restoration (case 2).

### **Case 1: Immediate Implant Temporization at the time of implant placement**

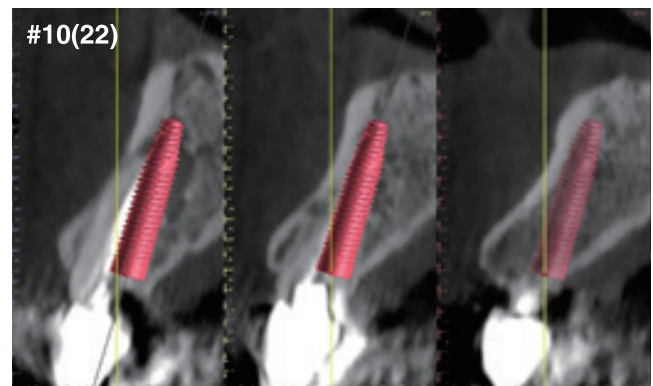
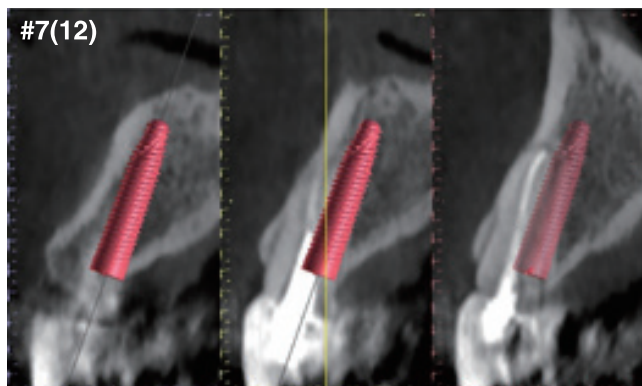
A 38-year-old male was referred for implants at sites #7(12) and #10(22). Both teeth had a long history of root canals, posts and constant loosening of restorations due to the lack of an adequate tooth structure for retention. The patient is a young professional who frequently gives presentations at his company, making him very aware of his smile and appearance.



Upon prosthetic evaluation, since both teeth were deemed unrestorable, the replacement plan was an implant-supported restoration. Radiographically, tooth #7(12) exhibited a moderate-sized periapical radiolucency.

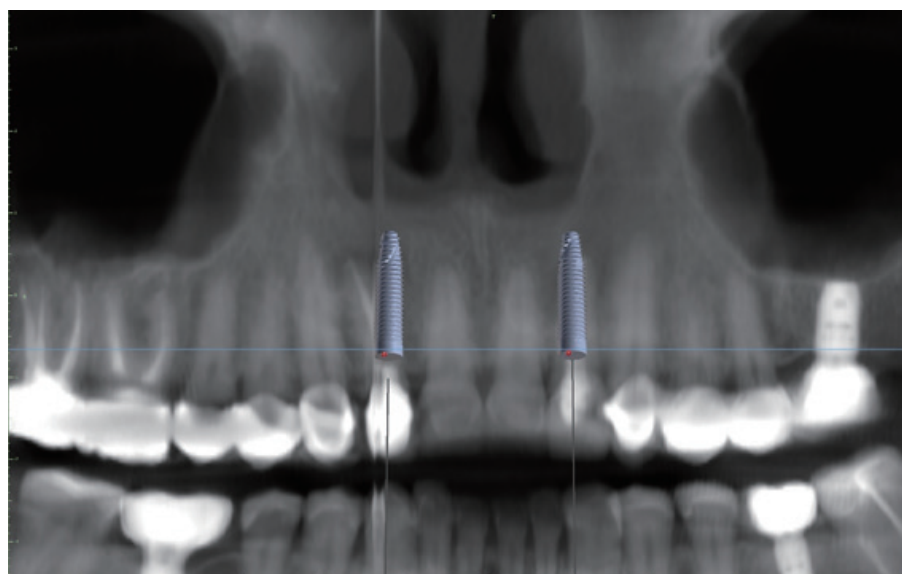
During the initial examination appointment, a CBCT and I-tero scans were obtained along with the appropriate shade to start planning an immediate nonfunctional temporary restoration. An intraoral scan was sent to the lab for digital planning of the temporary restorations.

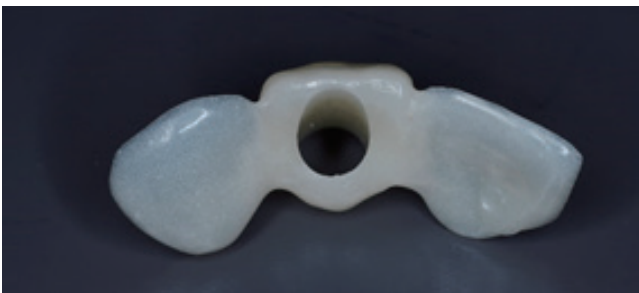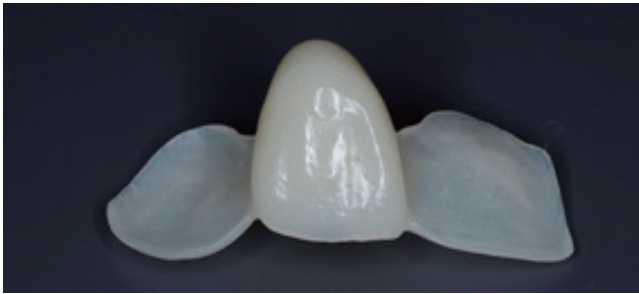A CBCT review showed adequate bone palatal to the socket wall, so the bone density appeared to be favorable for immediate implant placement.



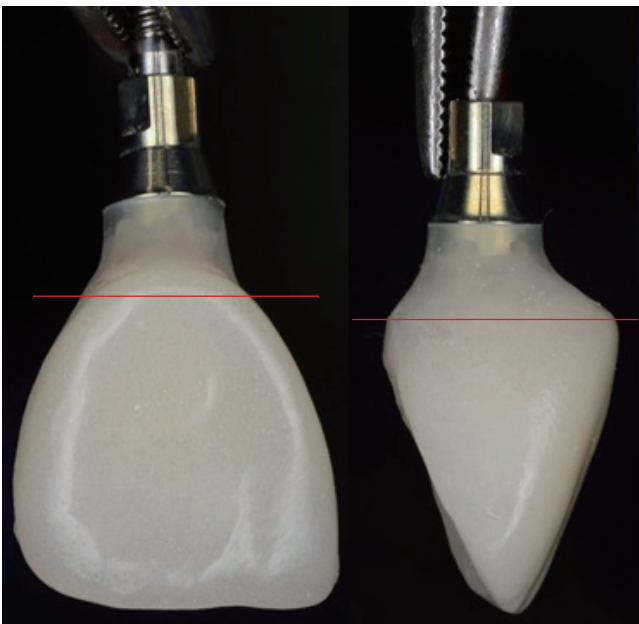A milled PMMA temporary shell was designed with an ideal screw access and built-in critical zone for the emergence profile. The screw access area was designed to fit the average diameter of a temporary abutment. This design decreases excessive adjustment of the shell.

The design of the temporary shell also included indexing wings which function to align the planned temporary restoration to the proper 3D orientation with perfect proximal contacts and no-centric occlusion restorations.





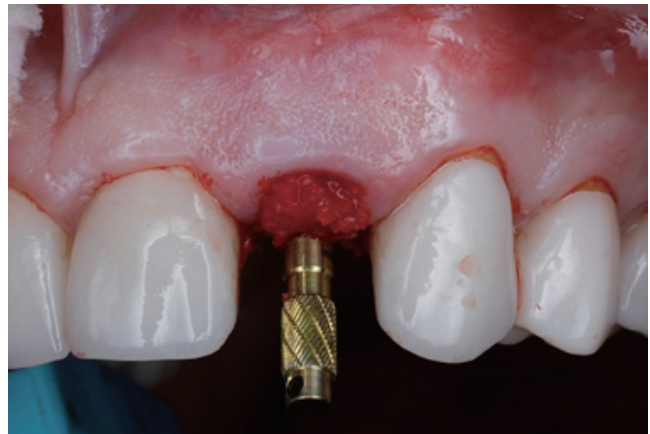
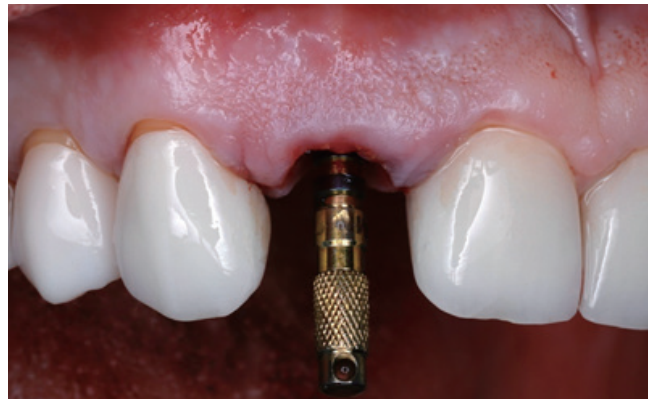Su et al. described two zones for implant provisional restoration: critical zone (most coronal aspect of the temporary) contour controls the gingival zenith placement, whereas the subcritical contour maintains and supports the peri-implant soft tissue volume..



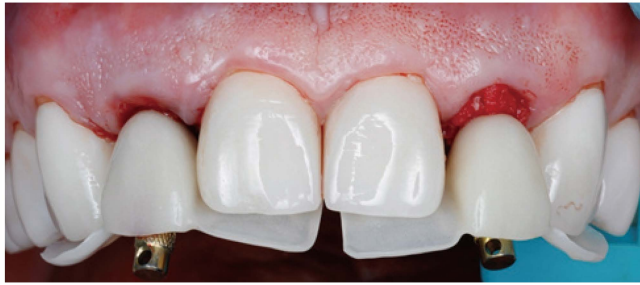The lab was specifically instructed to make the critical contour of the temporary shell about 0.5-1mm shorter than the ideal gingival zenith to allow for a slight coronal migration of tissue during the healing period. The final gingival zenith can be idealized during a further tissue training phase or with the final implant restoration.

During the surgical treatment phase, the teeth were extracted with the least amount of trauma to the soft tissue, especially to the papillae and gingival margins.

The sockets were thoroughly curetted and irrigated prior initiating the osteotomy, especially focusing on the sockets with existing periapical lesions. The placement of implants into sockets with periapical or periodontal infections can be done successfully with good curettage (Chrcanovic 2015).



Both sites were prepared into the solid palatal wall of the socket and the osteotomies were under prepared to achieve a minimum high insertion torque of at least 30N to be considered for non-functional immediately loaded temporization. 4.0x16mm implants were placed with an insertion torque above 50N at both sites. The jump gaps were grafted with cortical-cancellous allograft (Life-Net Salvin) in a dual zone fashion. The most coronal zone was packed with a moderate force to create more volume in the soft tissue compartment.

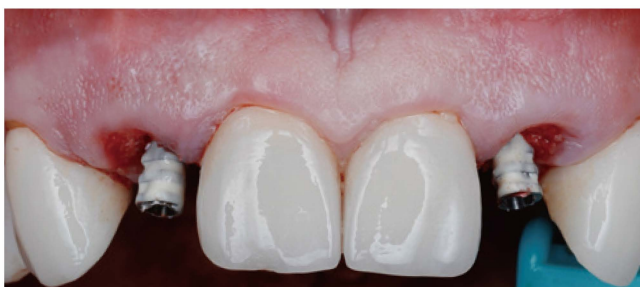

During placement, temporary shells can be used as surgical guides to confirm the appropriate implant positioning prior to the implant going to the final depth of the osteotomy. If the angulation is not ideal, some modification can be made, while still being able to maintain a high insertion torque.

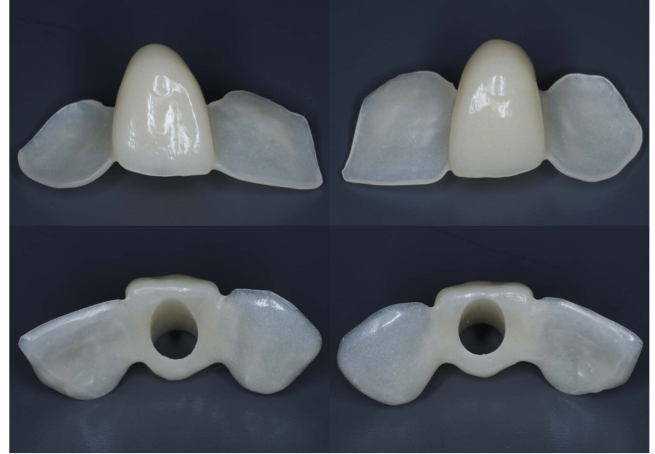The implant must be planned and executed with a high precision as regards the position, angulation and depth in order to utilize the lab-made custom temporary shells successfully.

The preferred depth of implant placement should be at least 3-4mm apical to the proposed facial gingival zenith (Linkevicius). An appropriate implant placement depth is crucial to provide adequate running room for the temporary and final restorations, a concave emergence with an adequate jump gap with the appropriate "regenerative space" (Gonzalez-martin) during dual zone grafting (Tamow). In thin tissue phenotypes or in cases with pre-existing recession, soft tissue augmentation utilizing a connective tissue graft can be done at this time. Due to a favorable phenotype and the absence of any soft tissue defect, this case didn't need a soft tissue graft.

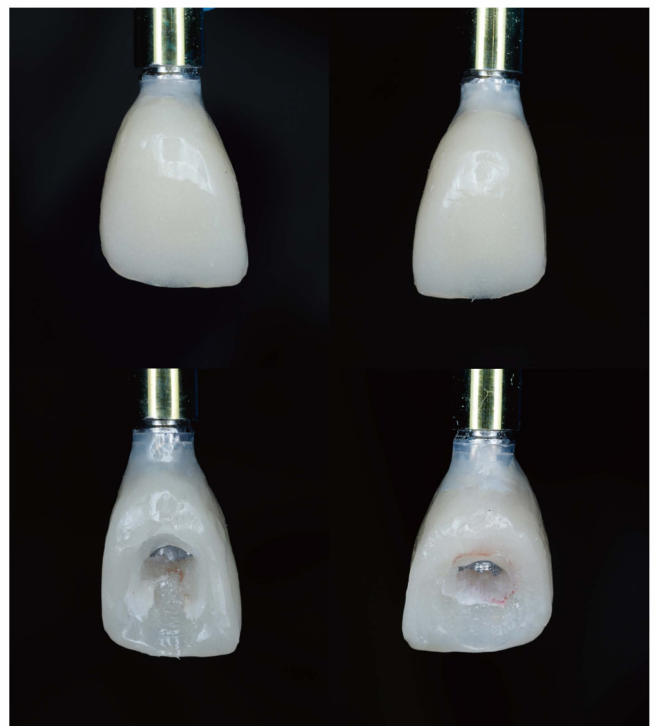Upon insertion of the temporary abutments, a radiograph should be taken to confirm adequate seating, if the seating of the abutments is not passive, confirm that the surface of the abutment is not impinging on the socket walls. Profiling the bone may be needed in some cases to prevent the formation of a bony defect due to the proximity of the restorative abutment to the bony walls of the socket.



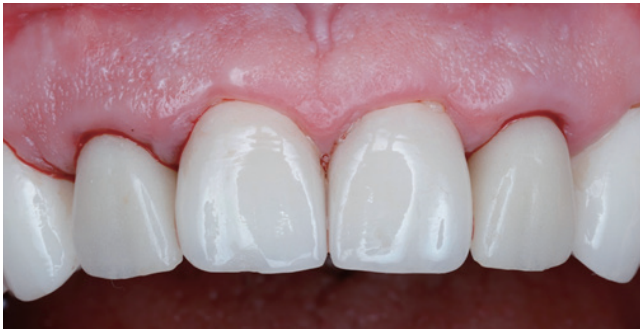Prior to the pick-up, liquid Opaquer (kerr) can be used to mask the metal hue of the temporary abutments if not using PEEK abutments.



Once both temporary abutments were passively seated, the temporary shells were adjusted to be seated over the abutments freely. Sometimes some adjustment can be needed to increase the diameter of the abutment hole.

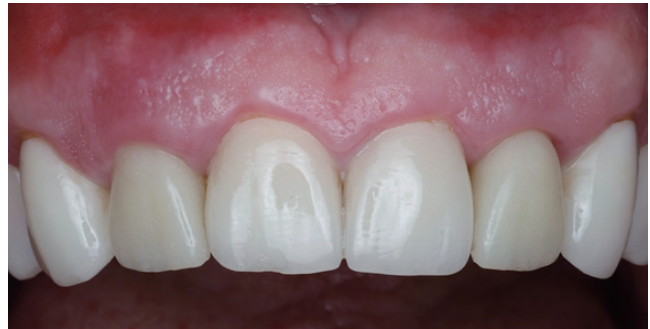

The custom shells were picked-up using a self-cure composite-based temporary material (Integrity), the wings can be removed at this stage, and the "sub-critical zone" of the emergence profile was customized chairside by hand using a flowable composite and football diamond bur.



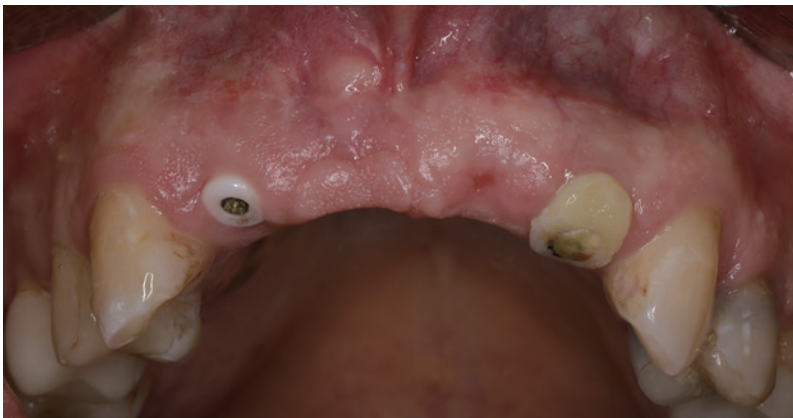The screw-retained temporary restorations were hand tightened to about 15N and sealed with Teflon tape and Fermit™ Temporary Filling Material.

There should be no centric or protrusive occlusal contact. If the adjacent teeth are periodontally compromised, I also prefer to have very light proximal contacts to avoid any micro movement from the adjacent teeth during normal mastication.



The 6 weeks follow-up showed stable soft tissue, no signs of inflammation, and good maintenance by the patient. The implants showed no mobility and appeared to be integrating uneventfully.

### **Case 2: Delayed Implant Bridge temporization after implant placement**

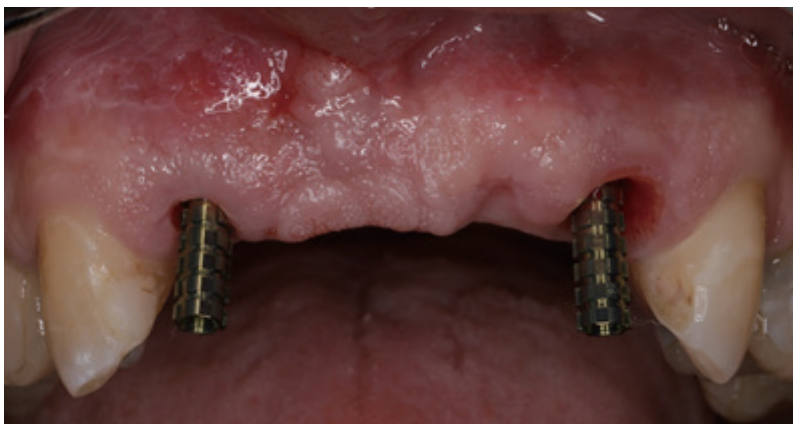

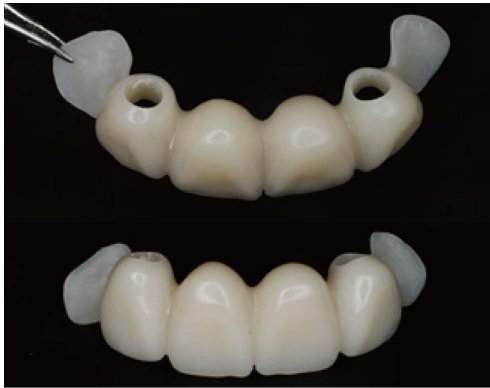Not all clinical situations present us with ideal immediate outcomes, and staging may be the only option. The initial plan for the following case was to extract the teeth, followed by immediate implant placement and a fixed temporary. However, due to a lower stability at implant #7, we decided to avoid temporalization until at least 2 months post implant placement.

The implants were placed immediately and the patient was given an Essix retainer to wear for at least 6 weeks post implant placement.

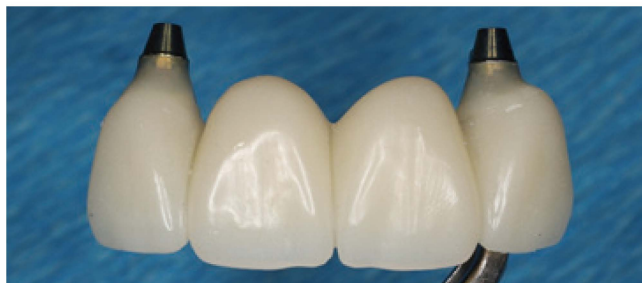
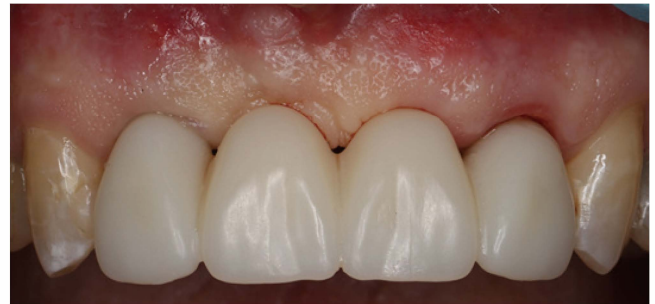Since the temp shells were already fabricated, we were ready to pick-up the temporary prosthesis using non-engaging temporary abutments.

When picking-up a multiple-unit bridge on temporary abutments, never use a flowable composite due to possible shrinkage of the material. Only use a self-curing no-shrinkage resin-based material (Integrity).

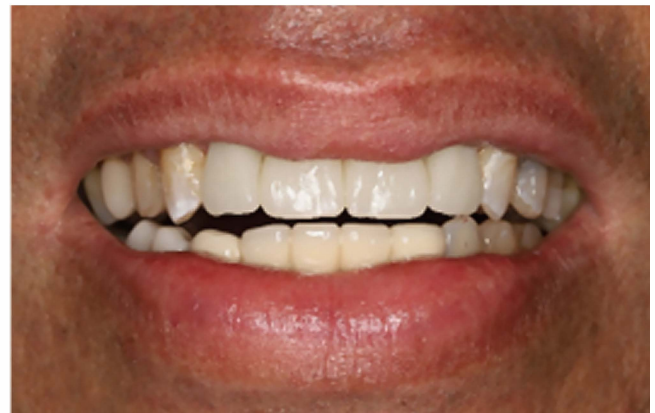



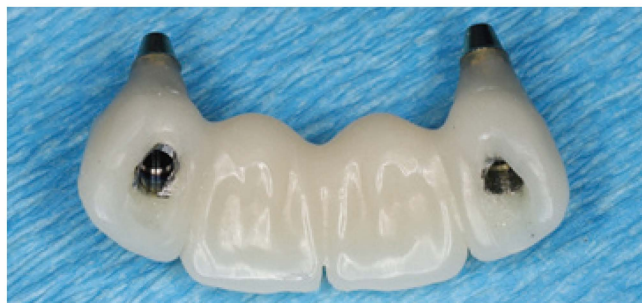Upon delivery of the prosthesis, some blanching is a good sign of tissue compression in needed areas (usually proximally), which starts the process of tissue training.



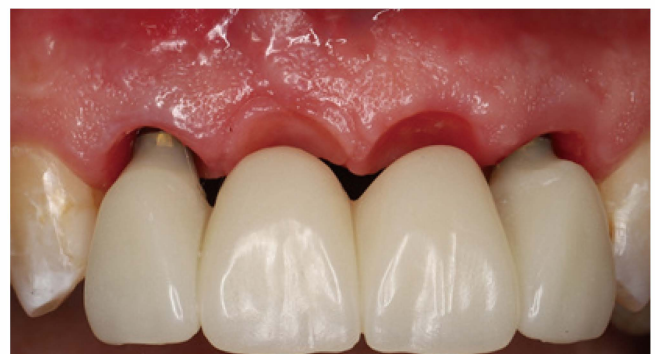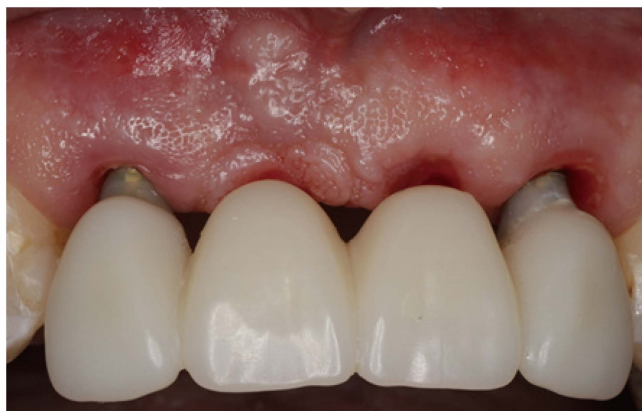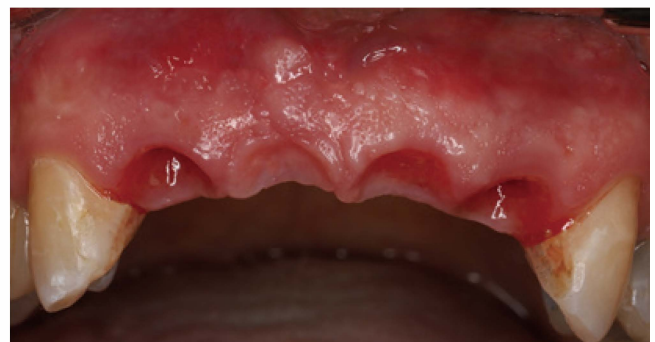Once the temporary was picked-up and the emergence profile was customized to provide adequate regenerative space and a properly placed critical contour (0.5 short of the final gingival margin), we were ready to deliver the prosthesis.

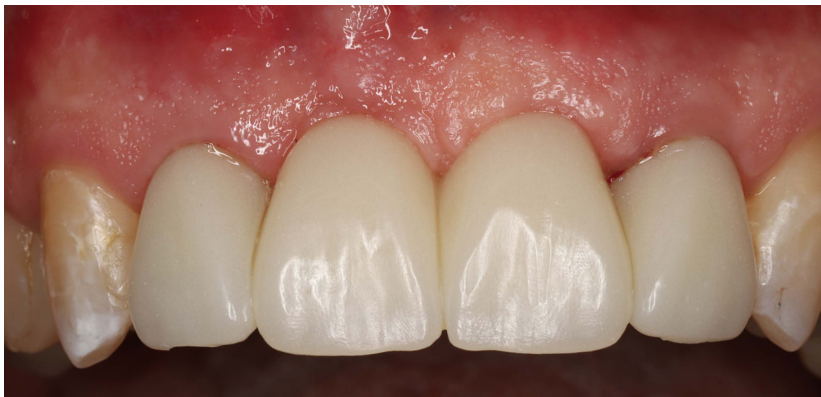

After 3 months of tissue training, the patient returned for a final evaluation prior to the final restoration.



Prior to delivery, make sure to leave a good amount of room in the embrasures to allow for soft tissue fill during the training period.






The patient was ready to proceed with the final restoration, and was referred back to his restoring clinician for his final bridge.

### Final Thoughts-----

The digital workflow advances in implantology now allow us to provide much faster, more predictable and highly esthetic results from immediate single tooth replacement to full -arch reconstruction. Implantology in the esthetic zone demands a seamless transition from teeth to implant-supported restorations with superior preservation or augmentation of hard and soft tissues. Besides a proper 3-dimensional placement of the implant, soft tissue management is a key component and implant temporization is an important category of soft tissue management. Digitally designed implant provisional shells with indexing wings are an efficient tool for the immediate preservation or redevelopment of the soft tissue emergence profile in immediate or delayed implant protocols.



PERIOIMPLANT\_LA

Board Certified Periodontist and Implant Specialist

#### Contact

**Dr. Dmitriy Ivanov, DDS**

Address: 16055 Ventura Blvd. Suite 405 Encino, CA 91436

Email: [Dmitriyivanov.dds@gmail.com](mailto:Dmitriyivanov.dds@gmail.com)

Instagram: [perioimplant\\_LA](https://www.instagram.com/perioimplant_LA)

Web: [www.perioamigos.com](http://www.perioamigos.com)