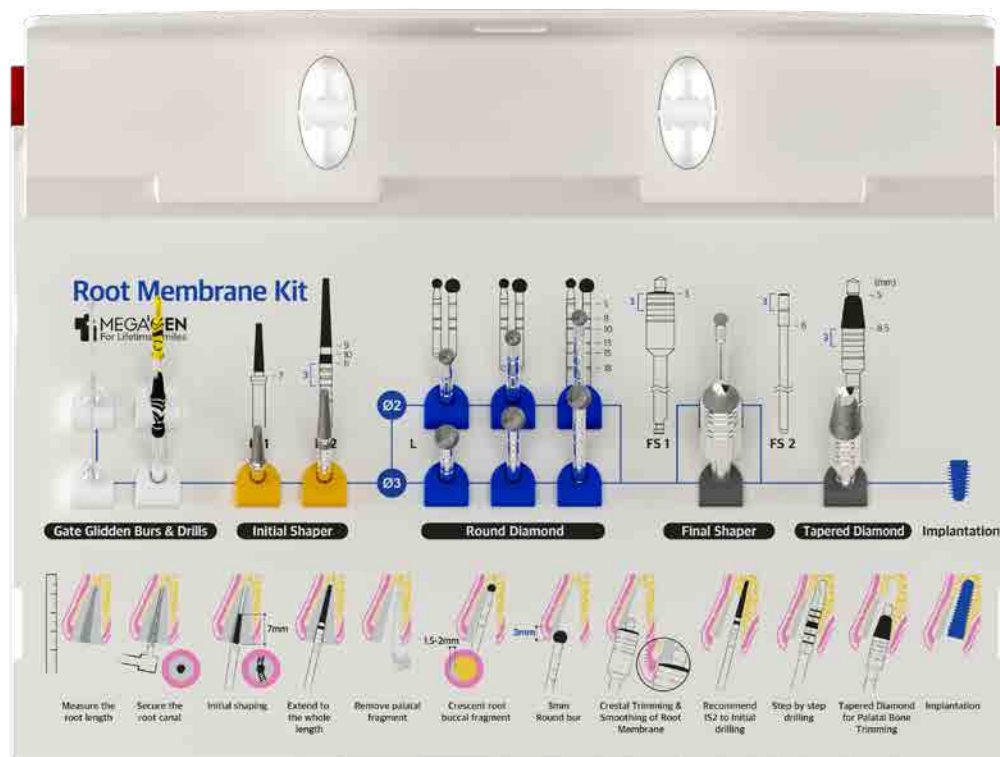


Root Membrane Kit

by MEGA'GEN



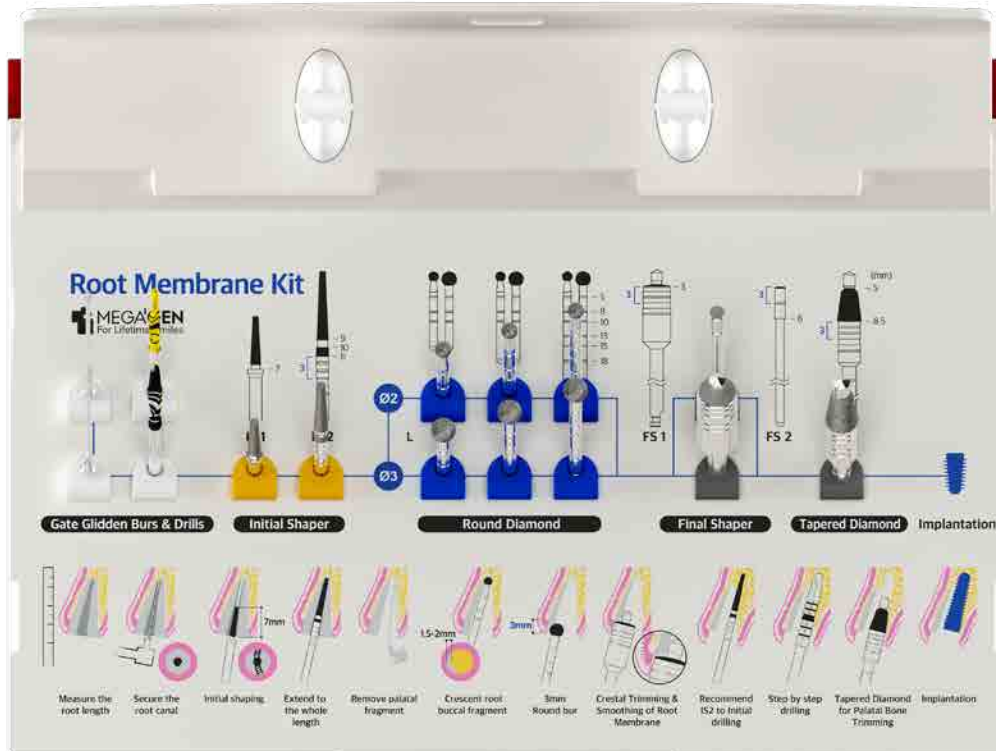
Root Membrane Kit

I. Root Membrane Kit

The best result of Immediate Implant Placement in esthetic zone.

Save the time & See an exceptional esthetic effect.
Root Membrane KIT is the answer for you!

| Ref.C |
|-----------|
| RMK3000CS |
| RMK3000MM |
| RMK3000HY |
| RMK3000CH |
| RMK3000KB |



We made it !

• **Dr. Yoshiharu Hayashi**

- Member/Diplomate and ICOI Japan Advanced Credential
- Commission of International Congress of Oral Implantologists
- Visiting Professor, Nihon University School of Dentistry at Matsudo
- Private practice in Tokyo & Chiba Province

• **Dr. Kwang Bum Park**

- AAP International Member
- Active Member - Academy of Osseointegration (AO)
- Director of Japanese Association of Dental occlusion
- Professor of Implant & Periodontic Surgery, MINEC
- Chief Director of MIR dental hospital, Daegu. South Korea.
- CEO - MegaGen Implant Co., S. Korea

• **Dr. Chang Hoon Han**

- Residency, oral and maxillofacial surgery, Chunnam National University Hospital
- Visiting professor, School of dentistry, Chunnam National University
- Visiting instructor, Chunnam National University
- Director of MIR dental hospital, Kyung-san. South Korea.
- Active Member of MINEC (MegaGen International Network of Education & Clinical research)

• **Dr. Konstantinos D. Siormpas**

- Graduated from the Dental School of Aristotle University of Thessaloniki.
- Private clinic in Larisa since 1978.
- Board member of Stomatological Society in Thessaly
- Founded a dental clinic called "Dental Care" with emphasis on surgical and prosthetic part of implantology and aesthetic dentistry in 2003
- Active member of the EDA (European Society of osseointegrated implants)
- Associate editor in the journal European Journal of Dental Science

• **Dr. Mitsias E. Miltiadis**

- Graduated from New York University Department of Periodontology and Implant Dentistry
- Master's Degree in Biomaterials & Biomimetics from the Department of Biomaterials at NYU.
- Achieved Dr. Med. Dent from University of Kiel in Germany on Biomaterials.
- An adjunct Instructor position at NYU Department of Periodontology and Implant Dentistry
- Member of Young MINEC Class 2013 (MegaGen International Network of Education & Clinical Research)

► Root Membrane Technique

- Courtesy of Dr. Siormpas & Dr. Miltiadis E. Mitsias

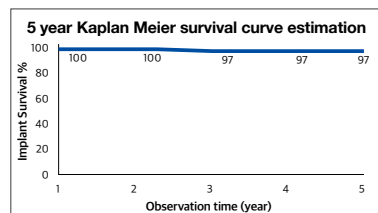
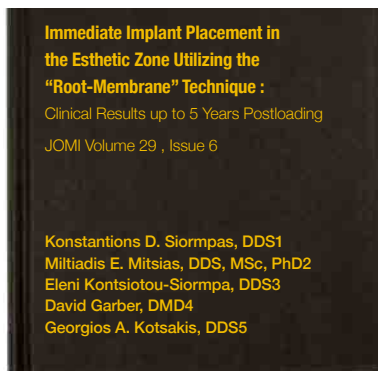Root Membrane technique is a surgical procedure performed before implant placement to induce successful osseointegration as increasing the soft tissue aesthetics by minimizing the loss of the buccal bone after extraction.

It separates the root at the time of extraction and leaving the root partially in the buccal side.

Therefore, it is possible to maintain the physiological relationship with the buccal side without deteriorating.

- The surgical procedure is currently performed using various techniques and instruments, however, since it is difficult to perform, it is considered an area that only skilled dentists can do.

- Through the step-by-step customized Diamond drill and simple guide, the tissue might entirely protected with the precise tooth modification. We released this KIT aiming to make the surgical procedures that had required intricate technique much easier.



The buccal side of Immediate implant placement in the anterior maxilla, there are Cementum, PDL, Attachment fibers, Vascularization, and Bundle bone maintained. Therefore, it leads continuous and predictable osseointegration by minimizing the loss of the buccal bones caused by socket remodeling that occurs after extraction.

According to a study published in JOMI, RMT is an alternative treatment method for Immediate placement techniques in aesthetic part. It has extremely high success rate compared to the implant placement after extraction.

As the study shows, the reason is that when the buccal root fragment is intentionally left the blood supply will be maintained smoothly and consequently the dimensions of alveolar ridge can be preserved. On the basis of this evidence, we can conclude that Root Membrane Technique is a safe treatment yields a high implant success rate.

Also, this unique technique can ensure the dimensional stability of facial and soft tissues around the implant site without using of the supplementary biomaterials such as bone grafts. Dento-gingival fibers retained in the root fragment increases soft tissue aesthetics when they are in process of esthetic Immediate implant placement.

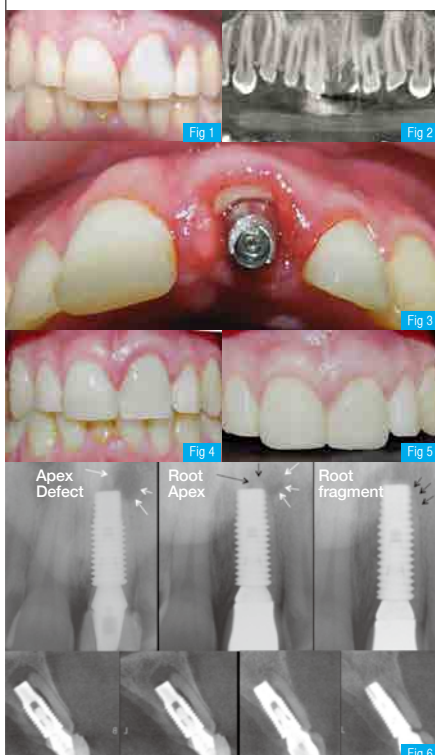


Fig. 1 The clinical feature before surgery of the maxillary left central incisor which is planned for extraction due to significant resorption.

Fig. 2 Cone beam CT section indicates consistent loss of tooth structure with invasive cervical root resorption.

Fig. 3 Immediate implant placement on the lingual side of the root fragment.

Fig. 4 Immediate loading after fixture placement.

Fig. 5 Follow-up for 2 years, the finally restored clinical photo. (Creeping attachment)

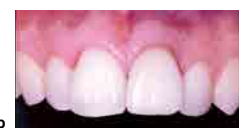Fig. 6 Top (Left to right)

The 24-month radiograph showed a limitation of defect size, while the resorption traces of apex did not appear radially. There was no sign of radiopacity consistent with the defect fill for 36 months. Apex resorption of root is confirmed.

Bottom (Left to right)

With 48 months of follow-up, the cross-section showed complete defect fill and about 1.5 mm root reabsorption. The reabsorption area is full of new bone cell with radiologic pattern and it leads new born growth.

10 years follow-up



“ Verify more Clinical Evidence of Root Membrane Technique which is certified a long-term clinical result ”

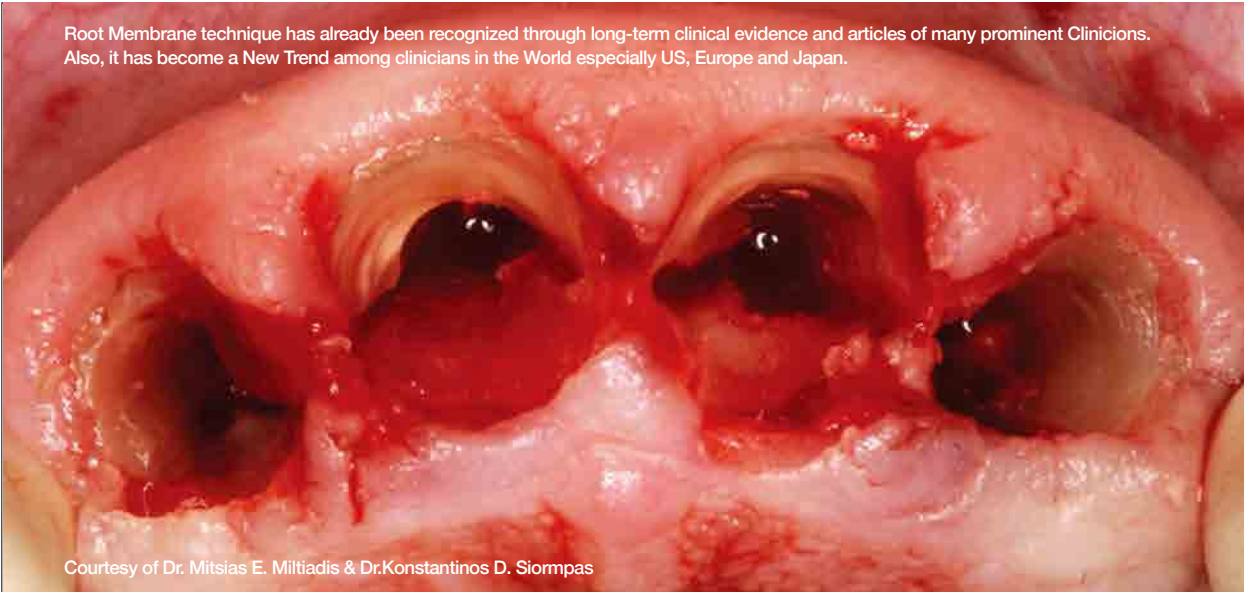
The socket-shield technique to support the buccofacial tissues at immediate implant placement
INTERNATIONAL DENTISTRY – AFRICAN EDITION VOL. 5, NO. 3
Howard Gluckman, Jonathan Du Toit, Maurice Salama

A Step- by-Step Description of PDL-Mediated Ridge Preservation for Immediate Implant Rehabilitation in the Esthetic Region
The International Journal of Periodontics & Restorative Dentistry VOL. 35, No.6
Miltiadis E. Mitsias, Konstantinos D. Siormpas, Eleni Kontsiotou-Siormpas, Hari Prasad, David Garber, Georgios A. Kotsakis

Advantages of the Root Submergence Technique for Pontic Site Development in Esthetic Implant Therapy
The International Journal of Periodontics & Restorative Dentistry VOL. 27, NO. 6
Maurice Salama, Tomohiro Ishikawa, Henry Salama, Akiyoshi Funato, David Garber

► Advantage of Root Membrane KIT

Root Membrane technique has already been recognized through long-term clinical evidence and articles of many prominent Clinicians. Also, it has become a New Trend among clinicians in the World especially US, Europe and Japan.



Courtesy of Dr. Mitsias E. Miltiadis & Dr. Konstantinos D. Siompas

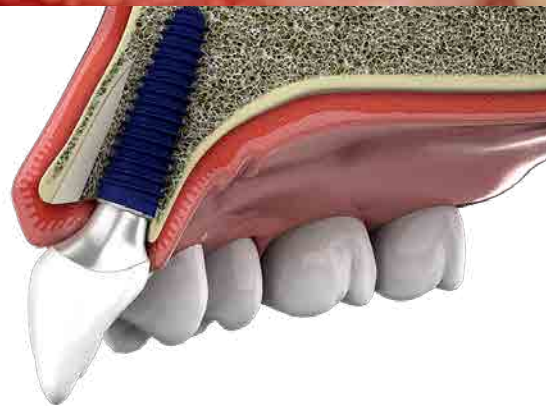
“Root Membrane technique”

“Socket Shield technique”

“Root Submergence technique”

“Partial Extraction Therapy”

Root Membrane KIT is the answer for you!



Best Diamond Drill for Root Membrane Technique

MegaGen’s Root Membrane Kit is made by combining the best quality of dental diamond drill technology from 50-year-old Japanese company called “Hinatawada Precision manufacturing.”

The reason why MegaGen selected Hinatawada is that it is a Japanese premium diamond drill company which has been recognized as one of the world’s top class products by the philosophy of craftsmen.

Also, Hinatawada has the most advanced technology for Root Membrane technique; no wobbling, cutting power, and durability that cannot be found anywhere in the world.

Advantages of MegaGen Diamond Drill

1. It does not give excessive vibration to the teeth, and you can get a smooth formed surface.
2. 3-4mm long diamond drill does not wobble when it is used at high speed rotation. (Rotation accuracy: less than 3 microns)
3. The sharpness of the diamond drill is maintained for a long time.
4. The diamond drill, which is made with high precision by grinding process, can be treated with the same feeling always because there is no deviation per product.
5. By increasing the hardness of the diamond drill, you can avoid the risk of bending during treatment, thus making it safer.
6. It has high rotation accuracy and small shaft vibration, so it prevents abrasion of the handpiece bearing part

Perfect match with AnyRidge

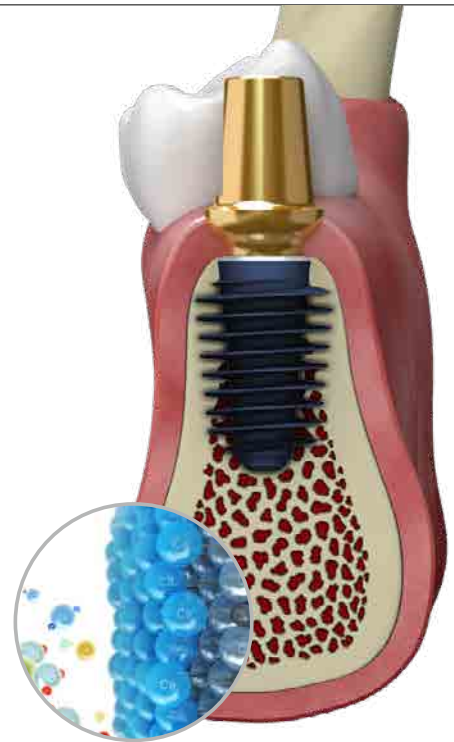
The strong point of Root membrane technique is Immediate Implant Placement. Strong initial stability guarantees a high success rate. AnyRidge Implant system of MegaGen and Root membrane technique is in harmony with strong initial stability and fast osseointegration.

AnyRidge Knife Thread Design

Knife Thread® with an oblique shape is designed of round face and narrow thread. Therefore, it can obtain an optimal ISQ because it is placed without damaging the unique architecture of cancellous bone. Also, it gives even stress distribution.

AnyRidge Xpeed Surface Treatment

XPEED® surface treatment technology is that the Ca⁺ ions which increase osseointegration rate on fixture surface can be reached through the chemical reaction with 0.5 micrometer thickness. Also, there is no problem of absorption of the coating layer after scaling deterioration, BIC and Removal Torque values are excellent.

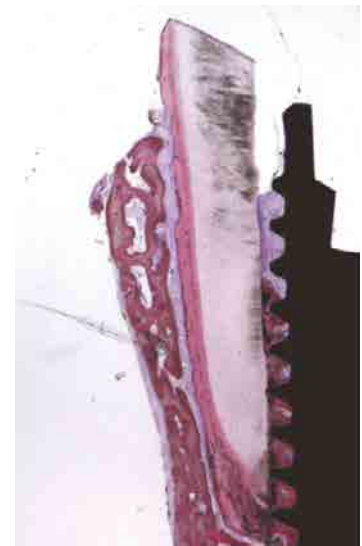


The Root Membrane Technique: Human Histologic Evidence after Five Years of Function

- Miltiadis E. Mitsias, Konstantinos D. SioRoot Membranepas, Gerogios A. Kotsakis, Scott D. Ganz, Carlo Mangano, Giovanna Iezzi

Our present human histologic study supports the assertion that the Root Membrane technique is effective in preventing bone resorption of the buccal bone plate of the anterior maxilla, five years after the placement of an immediate implant. This human histologic evidence that Root Membrane can preserve the buccal bone plate is of great value since it can help validate the clinical use of this surgical technique to maintain the hard and soft tissues over time and to optimize aesthetic results.

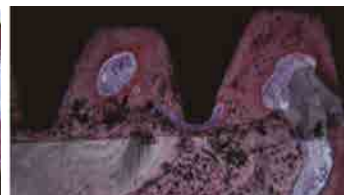
The retrieved tissue sample, which included the implant, the root membrane, the space between them, and the buccal bone plate, appeared intact. Only palatally to the fixture, and in the most coronal area, it appear evident that the trauma had detached the surface of the implant from the palatal bone; that area was of less importance for the present histologic evaluation and, therefore, the sample could be considered in perfect condition for histologic and histomorphometric analysis. The histomorphometrical evaluation showed a bone-to-implant contact of 76.2%.



Trabecular, mature bone at the interface of the implant was observed. The bone was present between the implant and the root. The root membrane and the buccal bone plate appeared intact without any signs of resorption.



Compact bone in the mediat thirds and apical portion of the implant were evident. No gaps were present at the interface.



In the apical portion of the root, it was observed that the cementum migrated from the residual root to the implant surface. Acid fuchsin-toluidine blue 40x.

Hindawi
BioMed Research International
Volume 2017, Article ID 7269467, 8 pages
<https://doi.org/10.1155/2017/7269467>

➔ Components for Root Membrane Kit

| Maximum Speed (RPM) of Drill | | |
|------------------------------|---------|--|
| R1 | 1,200 | 3DD50, 4DD4005, SD2018L, SD2518L |
| R2 | 30,000 | 2DD2034, 2DD3034 |
| R3 | 40,000 | 1DD1607, 1DD1911 |
| R4 | 100,000 | 2DD2025, 2DD2029, 2DD3025, 2DD3029, 3DD20H |

Gate Glidden Burs

- Separate purchase

- Featured product
- Dentsply | Gate Glidden Drill
- No.3 (Ø0.9) / No.4 (Ø1.1)



Shaping Drill

(Gate Glidden Drills)

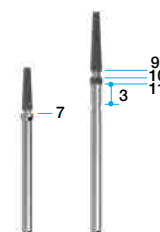
| RPM | Diameter | Length(mm) | Ref.C |
|-----|----------|------------|---------|
| R1 | Ø2.0 | 43 | SD2018L |
| | Ø2.5 | 43 | SD2518L |



Diamond Drill


(Initial Shaper)

| RPM | Diameter | Length(mm) | Ref.C |
|-----|----------|------------|---------------|
| R3 | Ø1.6 | 25 | 1DD1607 (IS1) |
| | Ø1.9 | 34 | 1DD1911 (IS2) |



Diamond Drill (Round Diamond)


| RPM | Diameter | Length(mm) | Ref.C |
|-----|----------|------------|---------|
| R4 | Ø2.0 | 25 | 2DD2025 |
| | | 29 | 2DD2029 |
| R2 | | 34 | 2DD2034 |
| R4 | Ø3.0 | 25 | 2DD3025 |
| | | 29 | 2DD3029 |
| R2 | | 34 | 2DD3034 |



Diamond Drill (Final Shaper)


| RPM | Diameter | Length(mm) | Ref.C |
|-----|----------|------------|--------------|
| R1 | Ø5.0 | 28 | 3DD50 (FS1) |
| R4 | Ø2.0 | 29 | 3DD20H (FS2) |

* FS1 Low Speed / FS2 High Speed



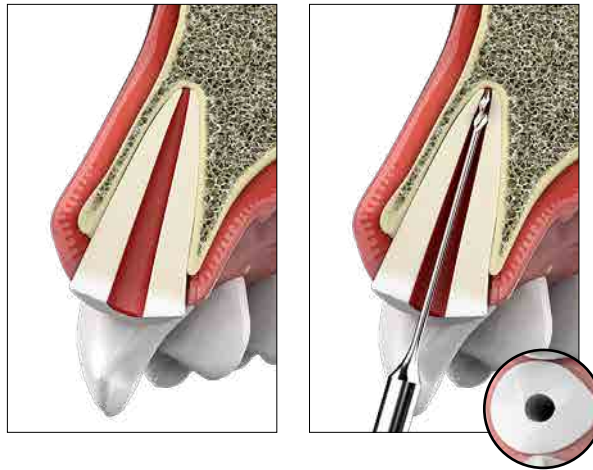
Diamond Drill (Tapered Diamond)

| RPM | Diameter | Length(mm) | Ref.C |
|-----|----------|------------|---------|
| R1 | Ø4.0 | 32 | 4DD4005 |

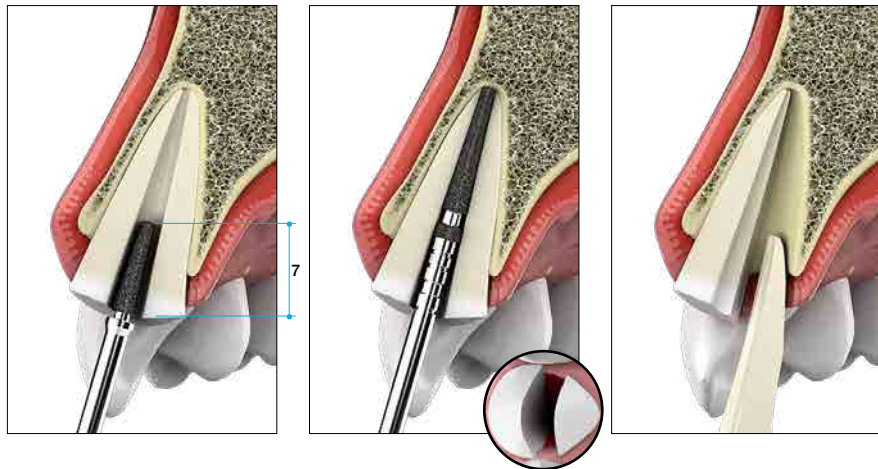


►► How to use Root Membrane Kit

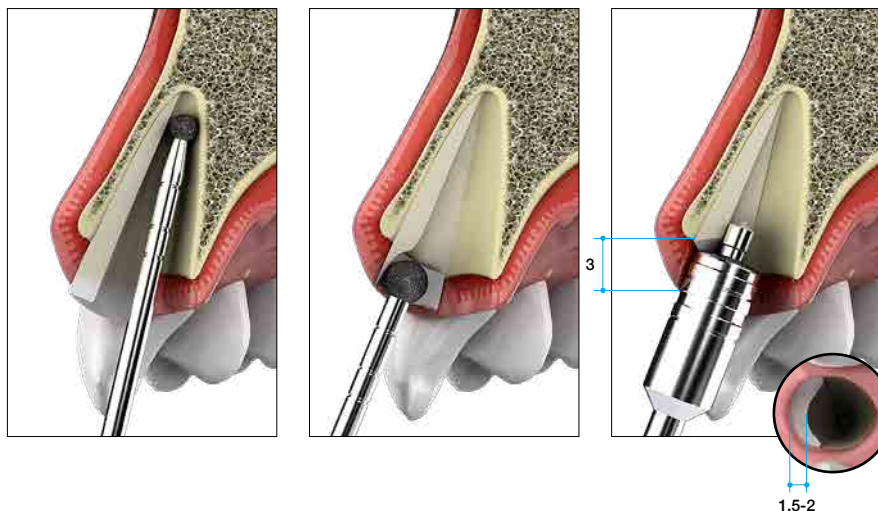
1. After measuring the length of root canal, secure the root canal using the Gate Glidden Drill and Bur.



2. Use Initial Shaper (IS1) to perform an initial root split about 7mm so that lingual surface becomes slightly rounded.



4. Use a round Diamond Drill that matches the length and size of the root fragment. Then trim the remaining roots forming a crescent moon when viewed from the occlusal surface. The ideal thickest central part of Root fragment is 1.5-2mm when viewed from the occlusal surface.

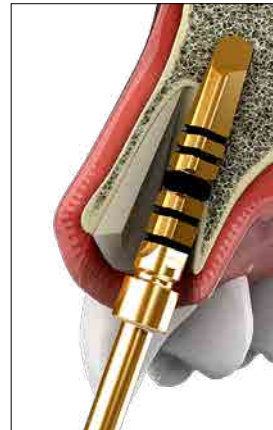
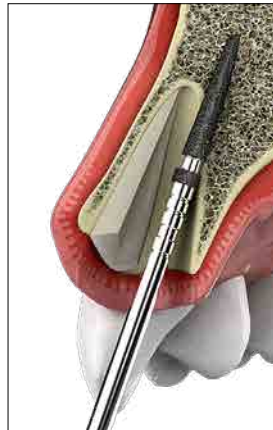
5. Perform the initial trimming so that the crestal part of the root fragment on the gingival part descends 3mm below the tip of gingiva.

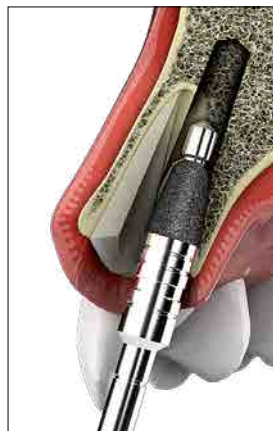6. Use the Final Shaper (FS1: for low speed or FS2: for high speed) to trim and smoothen the root fragment (Crestal) remaining below the tip of the gingiva.

7. To prevent slip of the common drill along the slot, initial drilling should be done using an initial shaper (IS2) after matching the direction in which the fixture is to be placed.

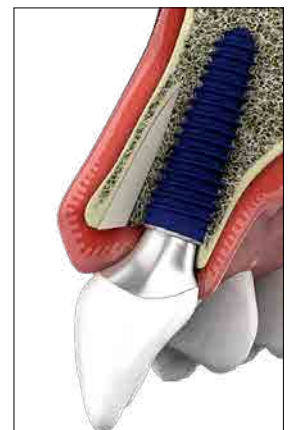
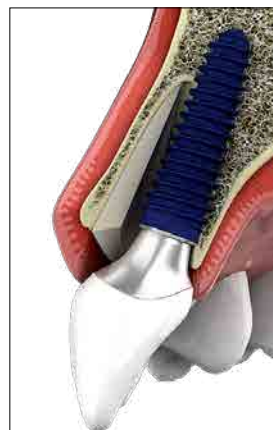
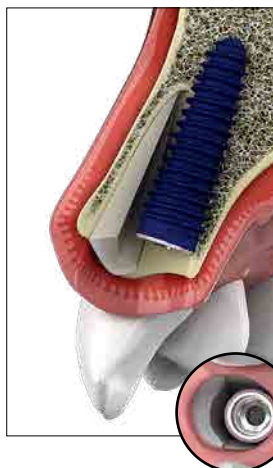8. After that, it needs step-by-step drilling.



9. Due to the feature of immediate placement, there is no resistance on the labial side, so labial shifting is likely to occur when the fixture is placed. To prevent this, trim the palatal side bone before fixture placement by using tapered diamond. It's kind of counter sinking drilling. You can adjust the depth of the tapered diamond according to the diameter of the fixture being placed.



10. Place the fixture without touching the remaining root fragment. If a gap between the root fragment and the fixture is wide, perform a little bone graft.



Root Membrane Clinical Case

➔ Clinical Case 1

- Courtesy of Dr. Yoshiharu Hayashi

Patient : 65 year old female

#7, 8, 9 on the left in maxilla have only roots remaining and #10 on the left is defective. As there were no residual tooth structure in the root region, it was highly likely the root would fracture even with new prosthesis (Figure 01, 02).

The plan was to have immediate placement after extraction with the root membrane technique for #7 on the right, delayed placement where placement is done after bone is matured for #10 on the left, and root membrane pontic for #8, 9

The sequence of the root membrane technique is to be revisited through this case.

Progress of Treatment

After cutting the roots of #7, 8, 9 on the left in maxilla mesio - distally with an ISF bur (Figure 03, 04), the palatal roots are removed.

Then, space should be created between the residual labial root fragments and the implants so that they do not touch with each other, and the surface of the root fragments facing the implants should be smoothed to facilitate bone regeneration. If it is trimmed with a round diamond bur it would be hard to make the surface smooth as bumps can be made.

Therefore, the root fragments should be trimmed using a root membrane bur that can create wide smooth surface (Figure 05). After that, the root fragments should be reduced up to the bone margin using a round diamond bur (Figure 06), and then 45 degree inclination should be made with a crestal trimming bur (Figure 07, 08).

As a result, gingiva will be inclined and the form of prosthesis can be relatively freely selected.

In summary, after forming the root fragments in 1-1.5mm thickness, the implant facing side should be trimmed smoothly followed by implant placement in a position where some space can be secured.

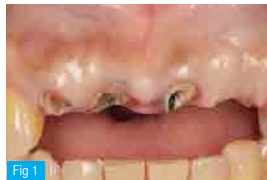

Fig 1 Intraoral frontal view at the first visit.

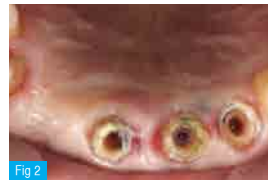

Fig 2 Intraoral occlusal view of anterior maxilla at the first visit. As only roots remained without healthy ferrule at #7, 8, 9 there was a very high risk of possible root fracture even if prosthesis were remade. Only root remained at #7, 8, 9

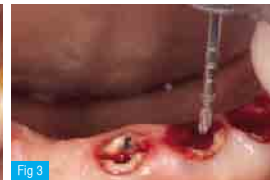

Fig 3 Residual root of #7, 8, 9 was divided mesiodistally using an ISF bur.

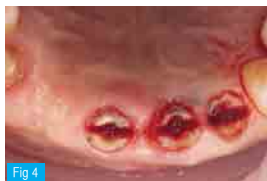

Fig 4 Residual root of #7, 8, 9 was divided mesiodistally.

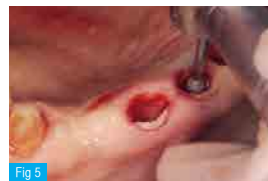

Fig 5 After removing the divided palatal root fragment, the inner wall of the labial root fragment was trimmed smoothly in thickness of around 1.5mm using a root membrane bur.

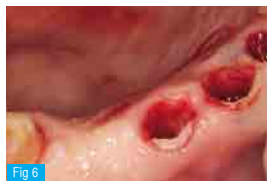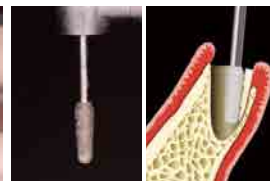


Fig 6 With a round diamond bur, the root fragment was prepared until its height was the same as the bone margin.

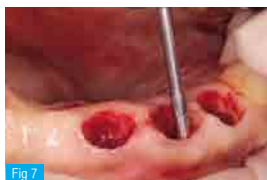
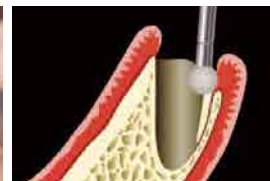
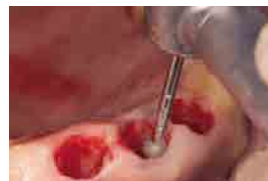Fig 8 About 45 degree inclination was given to the root fragment in the bone margin area using a crestal trimming bur. With this, gingiva would inline and the shape of prosthesis can be relatively freely chosen.

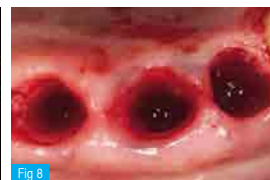
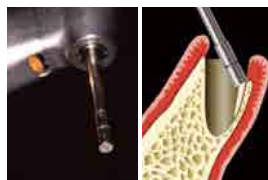
Fig 10 Completed root membrane.

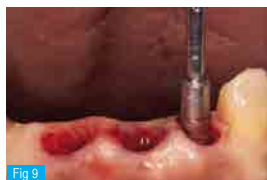

Fig 11 A placement hole needs to be formed while checking the bone quality of the site because initial stability is key to Implant success. The bone quality of #7 was checked first and a hole was drilled appropriate for the bone quality.

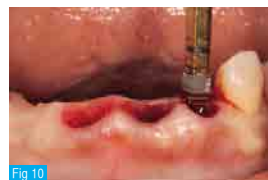
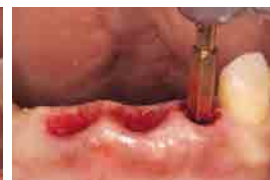
Fig 12 Implant was placed apically and palatally with around 60 Ncm torque.



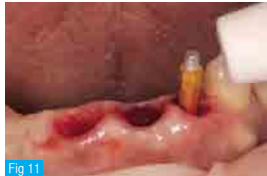

Fig 11

Implant Stability Quotient, ISQ, was over 70. ISQ can be used as an indicator to diagnose implant stability. The device uses RFA (Résonance Frequency Analysis) to measure and numerically represent the biomechanic property of bone tissue around implant and the strength of the interface between implant and bone. In general, low ISQ values, compared with the higher values, are considered to have higher risk of failure³.

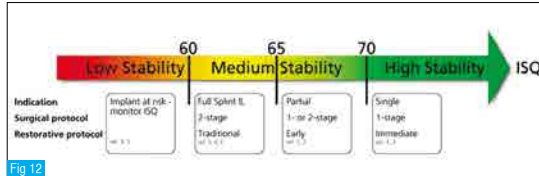


Fig 12

The relations between ISQ values and implant stability in bone.

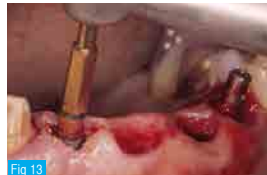

Fig 13

Delayed implant placement was performed after waiting for the bone to mature at #10. A hole was formed by checking the bone quality at this site too. During drilling, a straight abutment was temporarily inserted on the implant already placed at #7 and was used as a guide for parallelism.



Fig 14

Implant was placed apically and palatally with about 65 Ncm torque. The depth of placement was adjusted so that the platform was set at 4 mm below the gingival margin.

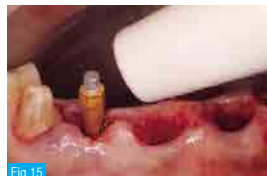

Fig 15

ISQ value was over 70.

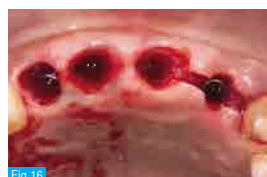

Fig 16

Occlusal view of anterior maxilla after implant placement. The Root membrane technique was used for #7, delayed placement for #10, and the Root membrane pontic for #8, 9.

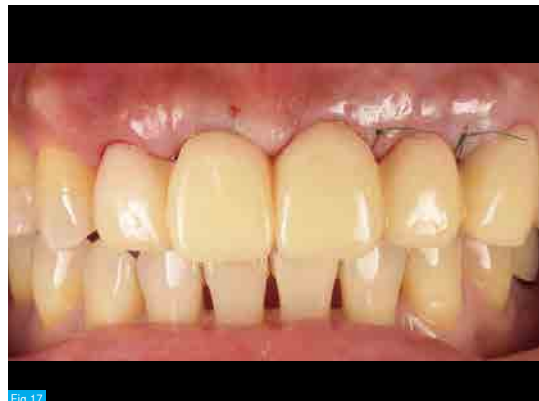

Fig 17

Intraoral frontal view immediately after surgery. Temporary restoration with contour adjusted to the patient's gingival line was delivered. As delayed placement was carried out at #10 after waiting for the bone to mature, subgingival form was Flat -contoured.

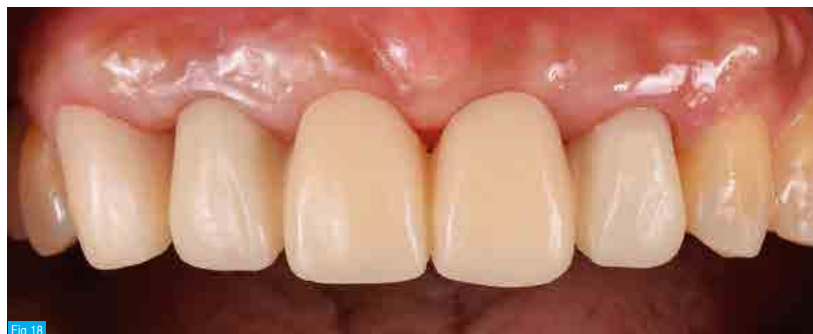

Fig 18

Intraoral frontal view #12 week post-op.

Implant is placed in a normal way but caution should be exercised during drilling as primary stability is crucial for Implant. It is important to drill the hole for implant by checking the bone quality of the site as bone quality varies depending on the location on the jaw bone. Especially in this case, as root membrane pontic installation was done for #8, 9 in the upper jaw at the same time to reduce the treatment time, immediate provisionalization would be impossible if implant primary stability is not obtained, lowering quality of life for patients during the treatment period.

In this case, after appropriate drilling is made by checking the bone quality of upper right #7 site, implant was placed palatally and slightly apically with the torque of 60 Ncm (Figure 09~11). Next, delayed placement was done at #10 on upper left by also checking the bone quality to create the hole for placement followed by implant placement palatally and slightly apically with the torque of 65 Ncm (Figure 02~16). The implant can be placed in parallel direction based on the temporary straight abutment mounted to the implant placed first at #7 on the right. As each implant showed ISQ 70 or more, it was determined good enough for immediate provisionalization.

Provisional restoration contoured according to the current gingival line right after the procedure was delivered. (Figure 17).

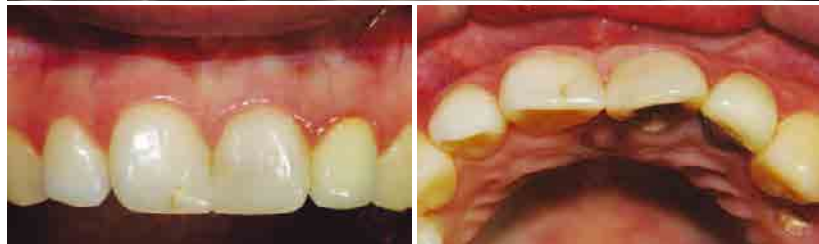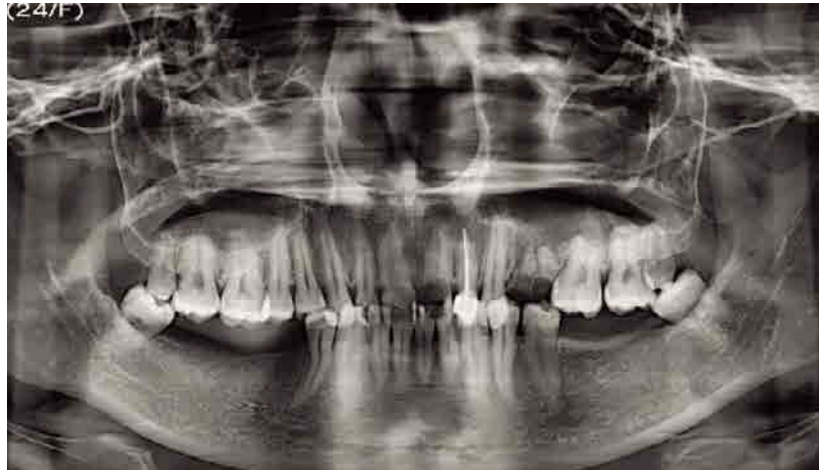
As delayed placement which awaits bone to mature was performed for #10 the subgingival form was under-contoured. Symmetric and eengineering was maintained 12 week post-op. (Figure 18).

➡ Clinical Case 2

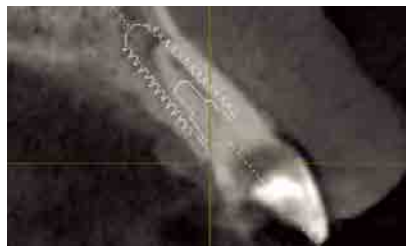- Courtesy of Dr. Chang Hoon Han

Case (24/F)

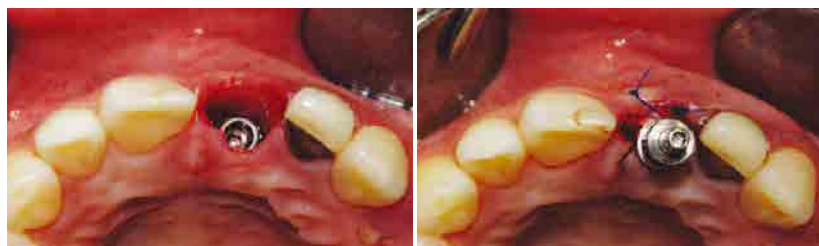A 24-year-old female patient came to the office complaining severe carries in the upper left central incisor crown area, and wanted implants for the tooth, maxillary left premolar and bilateral mandibular molar region.



Clinical pre-op photo. In this case, if immediate implant placement after extraction is to be planned, firstly atraumatic extraction should be made before drilling along the lingual wall of the extraction socket. Initial stability can be obtained more easily with tapered implant. The preferred method is to place autogenous bone graft or allograft into the gap between the buccal bone fragment and implant, and xenograft which is resistant to resorption on the buccal side of the buccal bone.



The buccal bone of the root was very thin on CT and was anticipated to be lost after extraction even if it were preserved during extraction. After discussing various treatment options with the patient, the minimally invasive "Root-membrane technique" which can obtain good outcome was chosen.

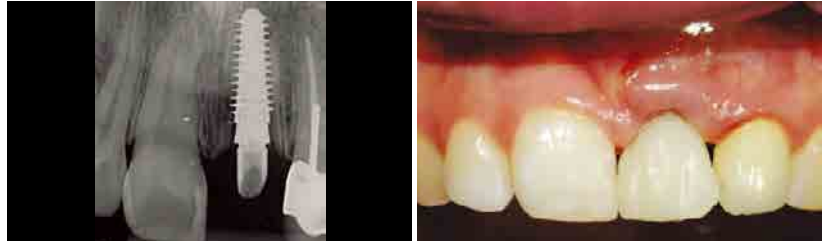

#21 : AnyRidge 4.5 x13 mm (ITV 50 N/cm, ISQ 72)

After decoronation and hemisection, lingual portion of the root fragment was removed and the remaining root fragment on the buccal side was trimmed to the crestal bone level. The lingual side of the remaining root fragment was smoothly trimmed using a diamond bur. In terms of root membrane thickness, the thickest central part should be 1.5 ~ 2 mm from the occlusal view.

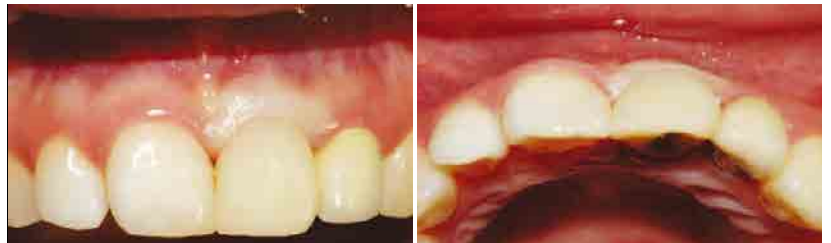As the implant was positioned 1~2 mm inferior to the bone margin, the bone margin of the root membrane was made inclined with a 45 degree angle palatally (lingually) before implant placement to enable proper formation of emergence profile for future prosthesis. Drilling was performed to place implant on the lingual side of the root membrane in a normal way. Before AnyRidge 4.5x13 mm was placed, final checking was done to see if the completed root membrane was mobile. Relatively large diameter implant was placed but a 2 mm or bigger gap existed between the implant and the root membrane remaining on the buccal side.

In general, it is recommended to fill the gap with autogenous bone graft or allograft. In this case, the top portion of the gap was simply blocked with absorbable hemostat and suturing was done minimally hoping the blood clot filling the gap would turn into bone later. The implant placement torque was 50 Ncm and the ISQ value right after the placement was 72. As the initial stability was good, pick-up impression coping was connected right after surgery for immediate provisionalization and impression was taken.



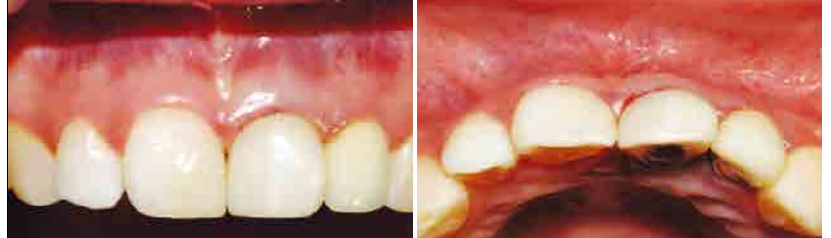OP + 1 day

On the next day of implant placement, provisional using temporary abutment was delivered and the patient was advised not to use the anterior region during the healing period.



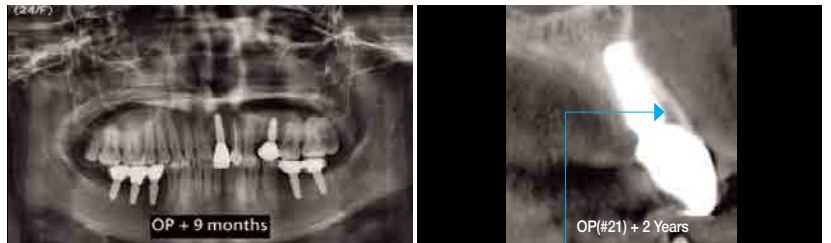OP + 8 months

At 8 month post-op, the provisional crown was modified to look similar to the final prosthesis.



OP + 9 months

The area around the implant prosthesis was confirmed to remain healthy without any sign of inflammation while provisional restoration period. At 9 month post-op, screw retained type final prosthesis was delivered. After the delivery of the final prosthesis, it was confirmed that continuity of the buccal bone to the adjacent teeth was maintained on the occlusal



OP + 9 months

At 9 month post-op, prosthetic treatment was completed for implants in the upper central incisors as well as upper left premolar and bilateral mandibular posterior region.

OP(#21) + 2 years

On the 2 year post-op CT, the very thin remaining buccal bone before the surgery was fused with the root membrane and resembled cortical bone (corticalization). Although the gap between the implant and the root membrane remaining on the buccal side was simply blocked with absorbable hemostat without any graft, it was filled with blood clot and was replaced by cancellous bone.

Root Membrane Kit

